SCIENTIFUR

SCIENTIFIC INFORMATION IN FUR ANIMAL PRODUCTION

Vol. 43, No. 3



IFASA

INTERNATIONAL FUR ANIMAL SCIENTIFIC ASSOCIATION

SCIENTIFUR scientific information for those involved in fur animal production is published by the International Fur Animal Scientific Association (IFASA).

SCIENTIFUR is the focal point for fur animal researchers all over the world and serves as a platform for scientific and other communication among researchers and others who are interested in the production of fur bearing animals. As such **SCIENTIFUR** contains reports of both basic and applied research as well as abstracts of publications published elsewhere and information regarding congresses, scientific meetings etc. A reference in Scientifur does not imply an endorsement by IFASA of the content, views or conclusions expressed.

SCIENTIFUR is published as four issues per year (one volume).

SCIENTIFIC ARTICLES. Papers forwarded can be published in Scientifur. The scientific content of the article is the sole responsibility of the author(s)

EDITOR'S ADDRESS. Articles for publication in SCIENTIFUR have to be forwarded to the Editor:

Vivi Hunnicke Nielsen
SCIENTIFUR
P.O Box 14
DK-8830 Tjele, Denmark

Tel: **+45 2219 1351**
E-mail: Scientifur@dca.au.dk

SUBSCRIPTION: Free of charge: http://www.ifasanet.org

TREASURER'S ADDRESS. Correspondence to the Treasurer should be addressed to:

Steen H. Møller
IFASA
P.O. Box 14
DK-8830 Tjele, Denmark

Tel: **+45 8715 7926**
Fax: **+45 8715 4249**
E-mail: IFASA@anis.au.dk

INDEXING: Titles that have been published in SCIENTIFUR are covered in an electronic SCIENTIFUR INDEX.

ISSN: 2445-6292

SCIENTIFUR
ISSN 0105-2403
Vol. 43, No. 3

Published by IFASA
INTERNATIONAL FUR ANIMAL SCIENTIFIC ASSOCIATION

Notes from the Editor

In some carnivores including mink, obligate embryonic diapause is seen at gestation. It is an evolutionary strategy ensuring development of the embryo and birth of the offspring under optimal maternal and environmental conditions. To obtain a better understanding of the termination of the embryonic diapause, global gene expression changes in the mink uterus were studied during embryo diapause and activation leading to implantation. The abstract with the results of this study is published in this issue of Scientifur. Another abstract describes a method for obtaining and culturing mink blastocysts, which is essential to further study the complex interaction that occur between the blastocyst and the uterus during diapause and reactivation.

Stereotypic and other inexpedient behavior reflect animal welfare. In a study with mink, neuronal activity data were correlated to stereotypic behavior but the results were not unambiguous. A study with Chinchilla showed that fur chewing is associated with increased heat flux through chewed areas and increased feed and water intake, and it was suggested that the disturbance in the maintenance of thermal homeostasis contributes to reduced animal welfare.

Several abstracts report on investigations of the possibility of transmission of pathogens between species, which may cause severe health issues. Thus, the results of a study suggest that avian avulavirus 1 can adapt to novel hosts. Pathogens in wild foxes were pointed at in more studies to be a risk to both human and domestic animal health.

Vivi Hunnicke Nielsen

Editor Scientifur

BREEDING, GENETICS AND REPRODUCTION

Admixture analyses and phylogeographic relationships reveal complete genetic distinctiveness of Polish farm and wild red foxes *(Vulpes vulpes)* and the North American origin of farm-bred individuals

Zatoń-Dobrowolska M.[1], Mucha A.[1], Morrice D.[2], Wierzbicki H.[1], Moska M.[1], Dobrowolski M.[3]

[1]Department of Genetics, Wroclaw University of Environmental and Life Sciences, Wroclaw, Poland.
[2]The Roslin Institute, University of Edinburgh, Easter Bush Midlothian, Scotland, UK.
[3]Institute of Animal Breeding, Wroclaw University of Environmental and Life Sciences, Wroclaw, Poland.

Anim Sci J. 2019 Jul; 90(7):827-839.
Doi: 10.1111/asj.13223. Epub 2019 May 13.

The Red Fox Y-Chromosome in Comparative Context

Rando H.M.[1,2], Wadlington W.H.[3], Johnson J.L.[4], Stutchman J.T.[5], Trut L.N.[6], Farré M.[7], Kukekova A.V.[8]

[1]Illinois Informatics Institute, University of Illinois at Urbana-Champaign, Urbana, IL 61801, USA.
[2]Department of Animal Sciences, College of Agricultural, Consumer and Environmental Sciences, University of Illinois at Urbana-Champaign, Urbana, IL 61801, USA.
[3]Tropical Research and Education Center, Agronomy Department, University of Florida, Homestead, FL 33031, USA.
[4]Department of Animal Sciences, College of Agricultural, Consumer and Environmental Sciences, University of Illinois at Urbana-Champaign, Urbana, IL 61801, USA.
[5]Department of Animal Sciences, College of Agricultural, Consumer and Environmental Sciences, University of Illinois at Urbana-Champaign, Urbana, IL 61801, USA.
[6]Institute of Cytology and Genetics of the Siberian Branch of the Russian Academy of Sciences, 630090 Novosibirsk, Russia.
[7]School of Biosciences, University of Kent, Canterbury, Kent CT2 7NJ, UK.
[8]Department of Animal Sciences, College of Agricultural, Consumer and Environmental Sciences, University of Illinois at Urbana-Champaign, Urbana, IL 61801, USA.

While the number of mammalian genome assemblies has proliferated, Y-chromosome assemblies have lagged behind. This discrepancy is caused by biological features of the Y-chromosome, such as its high repeat content, that present challenges to assembly with short-read, next-generation sequencing technologies. Partial Y-chromosome assemblies have been developed for the cat (*Felis catus*), dog (*Canis lupus familiaris*), and grey wolf (*Canis lupus lupus*), providing the opportunity to examine the red fox (*Vulpes vulpes*) Y-chromosome in the context of closely related species. Here we present a data-driven approach to identifying Y-chromosome sequence among the scaffolds that comprise the short-read assembled red fox genome. First, scaffolds containing genes found on the Y-chromosomes of cats, dogs, and wolves were identified. Next, analysis of the resequenced genomes of 15 male and 15 female foxes revealed scaffolds containing male-specific *k*-mers and patterns of inter-sex copy number variation consistent with the heterogametic chromosome. Analyzing variation across these two metrics revealed 171 scaffolds containing 3.37 Mbp of putative Y-chromosome sequence. The gene content of these scaffolds is consistent overall with that of the Y-chromosome in other carnivore species, though the red fox Y-chromosome carries more copies of *BCORY2* and *UBE1Y* than has been reported in related species and fewer copies of *SRY* than in other canids. The assignment of these scaffolds to the Y-chromosome serves to further characterize the content of the red fox draft genome while providing resources for future analyses of canid Y-chromosome evolution.

Genes (Basel). 2019 May 28; 10(6). pii: E409.
Doi: 10.3390/genes10060409.

Transcriptome Changes in the *Mink* Uterus during Blastocyst Dormancy and Reactivation

Cao X.[1], Zhao J.[2], Liu Y.[3], Ba H.[4], Wei H.[5], Zhang Y.[6], Wang G.[7], Murphy B.D.[8], Xing X.[9]

[1]Institute of Special Animal and Plant Sciences, Chinese Academy of Agricultural Sciences, #4899 Juye Street, Jingyue District, Changchun 130112, China.

[2]*Institute of Special Animal and Plant Sciences, Chinese Academy of Agricultural Sciences, #4899 Juye Street, Jingyue District, Changchun 130112, China.*
[3]*Key Laboratory of Embryo Development and Reproductive Regulation of Anhui Province, College of Biological and Food Engineering, Fuyang Teachers College, Fuyang 236000, China.*
[4]*Institute of Special Animal and Plant Sciences, Chinese Academy of Agricultural Sciences, #4899 Juye Street, Jingyue District, Changchun 130112, China.*
[5]*Institute of Special Animal and Plant Sciences, Chinese Academy of Agricultural Sciences, #4899 Juye Street, Jingyue District, Changchun 130112, China.*
[6]*Institute of Special Animal and Plant Sciences, Chinese Academy of Agricultural Sciences, #4899 Juye Street, Jingyue District, Changchun 130112, China.*
[7]*Institute of Special Animal and Plant Sciences, Chinese Academy of Agricultural Sciences, #4899 Juye Street, Jingyue District, Changchun 130112, China.*
[8]*Centre de recherché en reproduction et fertilité, Faculté de médicine vétérinaire, Université de Montréal, St-Hyacinthe, QC J2S 2M2, Canada.* [9]*Institute of Special Animal and Plant Sciences, Chinese Academy of Agricultural Sciences, #4899 Juye Street, Jingyue District, Changchun 130112, China.*

Embryo implantation in the *mink* follows the pattern of many carnivores, in that preimplantation embryo diapause occurs in every gestation. Details of the gene expression and regulatory networks that terminate embryo diapause remain poorly understood. Illumina RNA-Seq was used to analyze global gene expression changes in the *mink* uterus during embryo diapause and activation leading to implantation. More than 50 million high quality reads were generated, and assembled into 170,984 unigenes. A total of 1684 differential expressed genes (DEGs) in uteri with blastocysts in diapause were compared to the activated embryo group ($p < 0.05$). Among these transcripts, 1527 were annotated as known genes, including 963 up-regulated and 564 down-regulated genes. The gene ontology terms for the observed DEGs, included cellular communication, phosphatase activity, extracellular matrix and G-protein couple receptor activity. The KEGG pathways, including PI3K-Akt signaling pathway, focal adhesion and extracellular matrix (ECM)-receptor interactions were the most enriched. A protein-protein interaction (PPI) network was constructed, and hub nodes such as VEGFA, EGF, AKT, IGF1, PIK3C and CCND1 with high degrees of connectivity represent gene clusters expected to play an important role in embryo activation. These results provide novel information for understanding the molecular mechanisms of maternal regulation of embryo activation in *mink*.

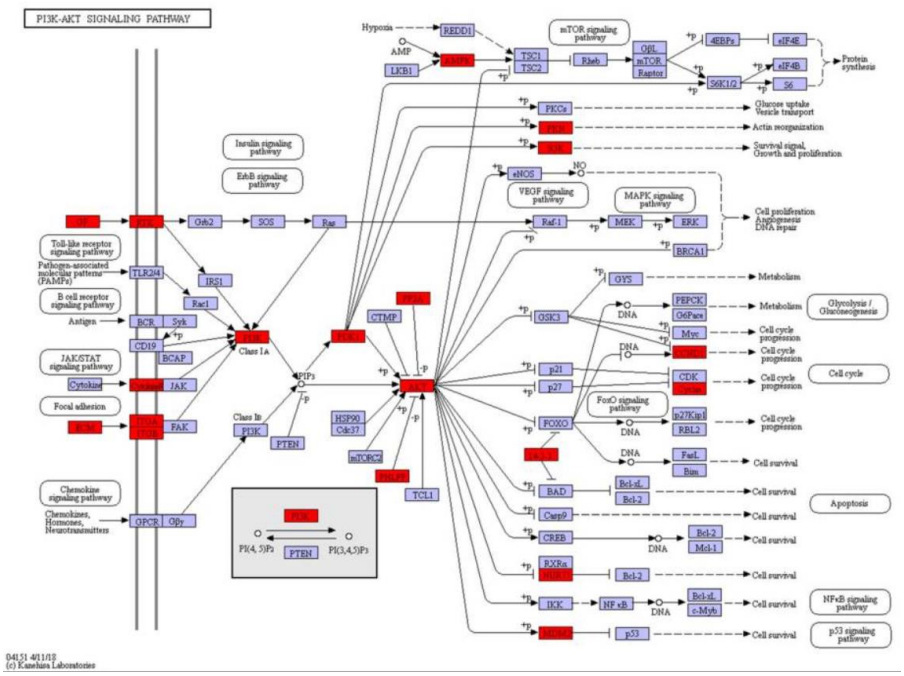

Fig. 1. Model of activation of the *PI3K/AKT* signalling pathway in *mink* uteri in activated versus diapause states. Differentially expressed genes are shown in red color. Genes in blue boxes were present in the *mink* transcriptome but not differentially expressed.

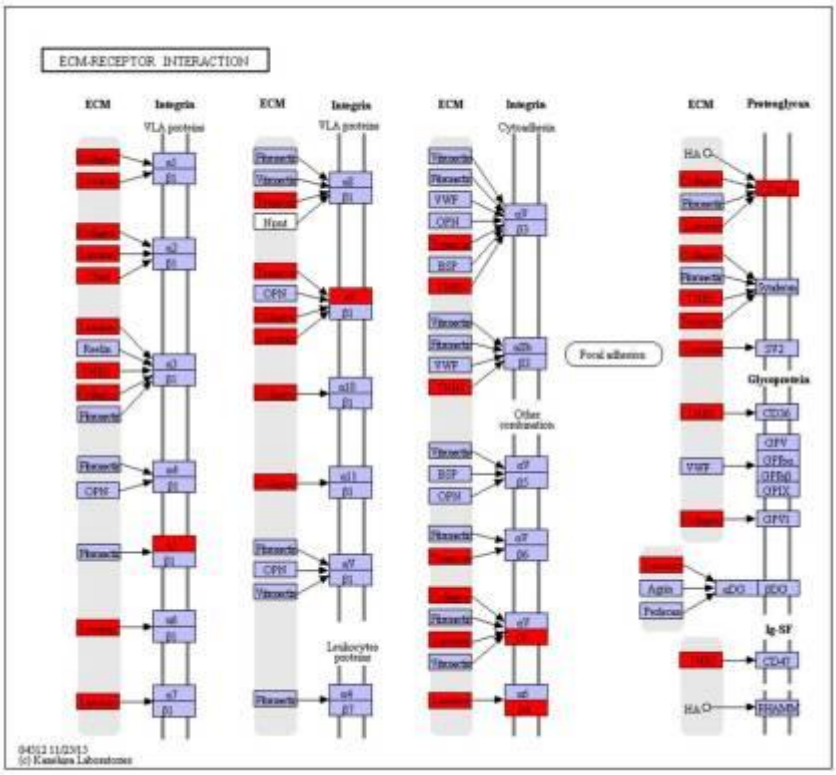

Fig. 2. Model of activation of the extracellular matrix (ECM)-Receptor interaction pathway in the *mink* uterus in activated versus diapause states. Differentially expressed genes are shown in red color. Genes in blue boxes were present in the *mink* transcriptome but not differentially expressed.

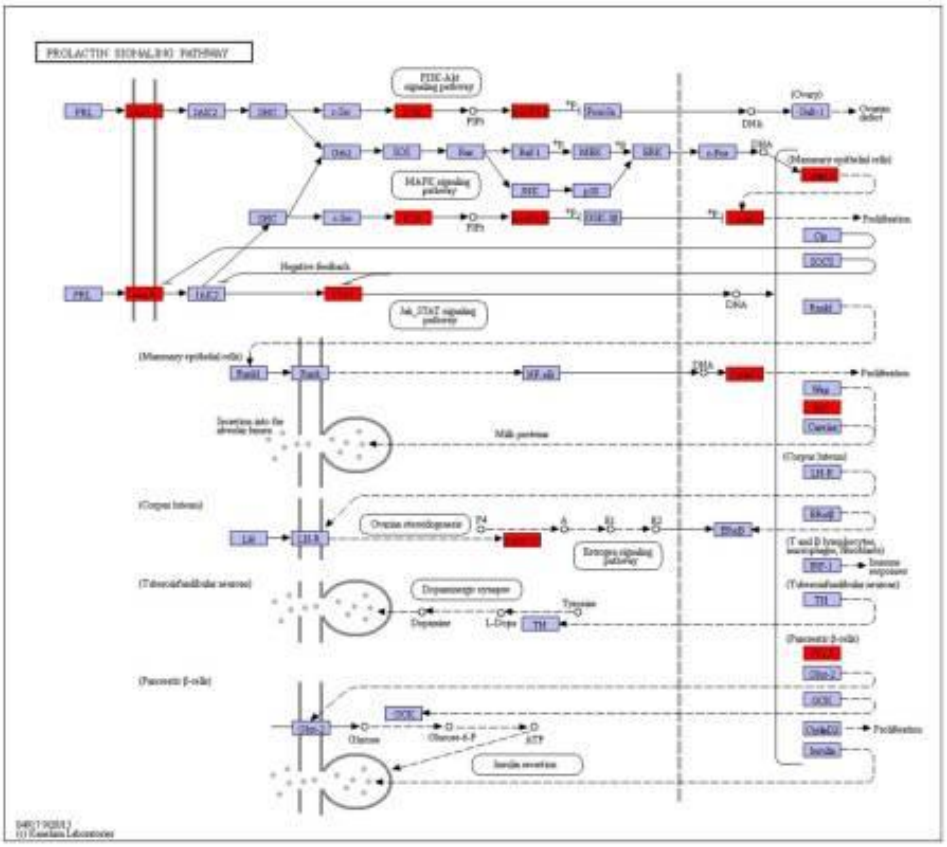

Fig. 3. Model of activation of the prolactin signalling pathway in the *mink* uterus in activated versus diapause states. Differentially expressed genes are shown in red color. Genes in blue boxes were present in the *mink* transcriptome but not differentially expressed.

Fig. 4. Connectivity degrees of the Protein-protein interactions (PPI) network.

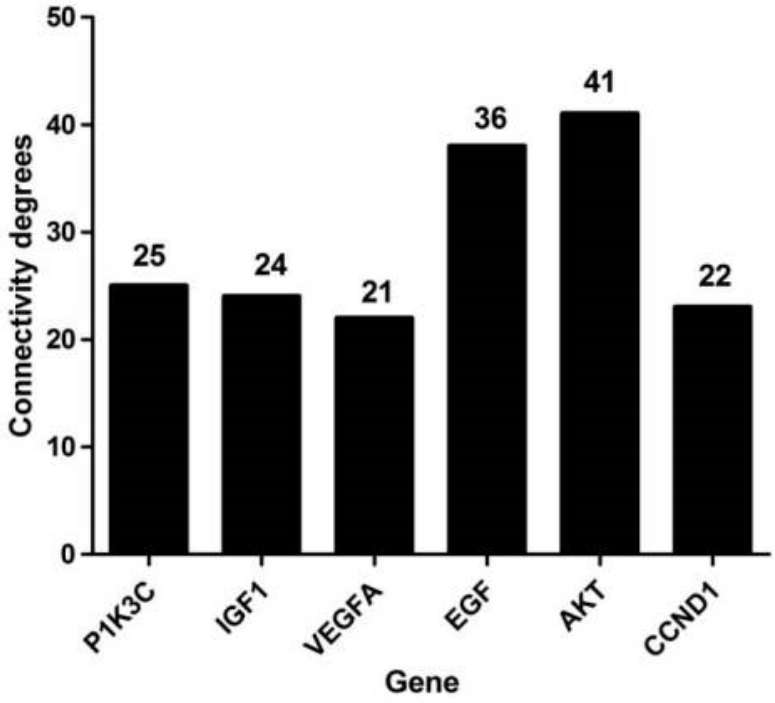

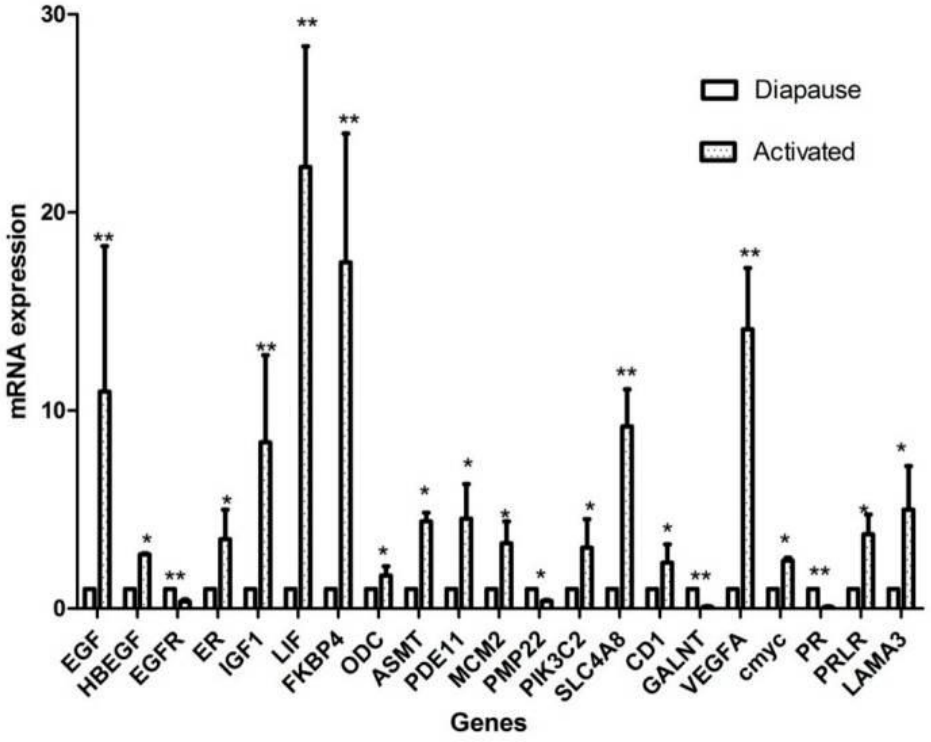

Fig. 5. QRT-PCR validation of RNA-Seq data in mink uterus during embryo diapauses and activation: activated/diapause expression ratios. GAPDH was used as the internal control for mRNA analysis. The data shown are from three biological replicates. * $p < 0.05$, ** $p < 0.01$.

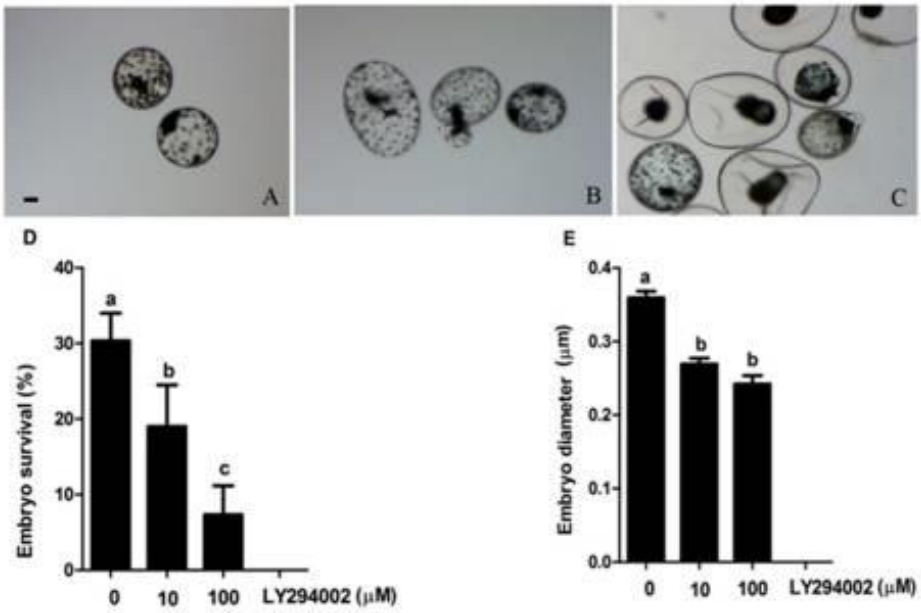

Fig. 6. *Mink* embryos recovered in obligate diapause and cultured with different concentrations of the *PI3K/AKT* inhibitor (LY294002). The morphology of embryos was evaluated under a stereomicroscope. (×200) (**A**) Diapause embryos, (**B**) Expanded embryos indicative of reactivation, (**C**) Dead embryos, (**D**) Embryo survival after five days culture, (**E**) The mean diameter of the blastocysts after five days culture. Significant at $p < 0.05$. Data are mean ± SEM. Different small letters above columns indicate significant differences by Student's *t*-test.

Int J Mol Sci. 2019 Apr 28; 20(9). pii: E2099.
Doi: 10.3390/ijms20092099.

Culture of Mink Preimplantation Embryos

Fenelon J.C.[1], Murphy B.D.[2]

[1]Centre de Recherché en Reproduction et Fertilité, Faculté de Médicine Vétérinaire, Université de Montréal, St-Hyacinthe, QC, Canada.
[2]Centre de Recherché en Reproduction et Fertilité, Faculté de Médicine Vétérinaire, Université de Montréal, St-Hyacinthe, QC, Canada.

The reproduction of the mink, Neovison vison, has been extensively studied over the past 70 years. The endocrine control of pregnancy is reasonably well understood, but our understanding of early embryo development is limited. The mink is one of the best characterized mammals for the study of embryonic diapause, but in order to unravel the complex interactions that occur between the blastocyst and the uterus during diapause and reactivation, a defined culture media system that supports growth is essential. Until recently, culture of the mink blastocyst has been relatively unsuccessful. This chapter will describe a method for successfully obtaining and culturing mink blastocysts and will highlight some of the unique challenges in working with this species. Methods to age match prediapause embryos in a mammal that exhibits superfetation, and to synchronize collection of reactivation from diapause stages using prolactin will be discussed. Finally, a quantitative method to determine the extent of cell proliferation in the blastocyst, a hallmark of reactivation from diapause, will be detailed.

Methods Mol Biol. 2019; 2006:269-277.
Doi: 10.1007/978-1-4939-9566-0_19.

Glycogen in the uterus and fallopian tubes is an important source of glucose during early pregnancy

Dean M.[1]

[1]Department of Animal Science. University of Illinois at Urbana-Champaign, Urbana, IL 61801.

Biol Reprod. 2019 Jun 14. pii: ioz102.
Doi: 10.1093/biolre/ioz102. Epub ahead of print.

Breeding Profiles at the Periparturient Stage in Captive Red Foxes (*Vulpes Vulpes*) Mating Naturally or Subjected to Artificial Insemination in Japan

Yatu M.[1], Sato M.[1], Kobayashi J.[2], Ichijyo T.[3], Satoh H.[3], Oikawa T.[4], Sato S.[3]

[1]Zao Fox Village Inc., Miyagi 989-0733 Shiroishi, Japan.
[2]Schools of Food, Agricultural and Environmental Sciences, Department of Farm Management, Miyagi University, Sendai, Miyagi 982-0215 Sendai, Japan.
[3]Cooperative Department of Veterinary Medicine, Faculty of Agriculture, Iwate University, Morioka, Iwate 020-8550, Morioka, Japan.
[4]Miyagi Prefectural Livestock Experiment Station, Miyagi, 989-6445, Shiroishi, Japan.

Introduction
Breeding profiles at the periparturient stage in red foxes which mated naturally or were subjected to artificial insemination were retrospectively surveyed using 130 vixens during their reproductive seasons of 2012-2017 in Japan.

Material and methods
Natural mating vixens were encouraged a maximum of three times with the same male, while artificial insemination was conducted using frozen-thawed semen with the bovine semen extender as a diluent.

Results
With natural mating, conception rates after one, two, and three copulations were 55.8%, 68.0%, and 85.7%, respectively, showing a significant difference between the rates for one and three copulations. Conception rates with artificial insemination were 82.4%. Mean gestation periods were between 52.1 and 53.3 days in all groups. Mean litter sizes were 3.7-4.3 cubs with natural mating, and 4.4 cubs with artificial insemination. Although some sporadic and inconsistent changes in litter sizes were noted between primiparous and multiparous groups, these were of doubtful clinical importance.

Conclusion
This is the first report from Japan concerning basic breeding events of red fox vixens in captivity.

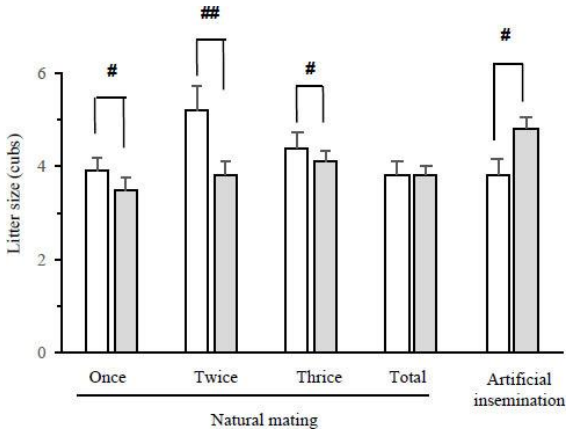

Fig. 1. Comparison of litter sizes between primiparous (open bars) and multiparous (grey bars) groups in cases of one, two, and three copulations (natural mating), and between them with artificial insemination in vixens. $^{\#}P < 0.05$ and $^{\#\#}P < 0.01$ *vs* the primiparous group (Student's *t*-test or Welch's *t*-test).

J Vet Res. 2019 Jun 12; 63(2):299-302.
Doi: 10.2478/jvetres-2019-0031.
eCollection 2019 Jun.

BEHAVIOUR AND WELFARE

Neurophysiological correlates of stereotypic behaviour in a model carnivore species

Díez-León M.[1], Kitchenham L.[2], Duprey R.[3], Bailey C.D.C.[4], Choleris E.[5], Lewis M.[3], Mason G.[2]

[1]Department of Pathobiology and Population Sciences, Royal Veterinary College, University of London, UK. Electronic address: mdiezleon@rvc.ac.uk.
[2]Department of Animal Biosciences, University of Guelph, Canada.
[3]Department of Psychiatry, University of Florida, USA.
[4]Department of Biomedical Sciences, University of Guelph, Canada.
[5]Department of Psychology, University of Guelph, Canada.

Behav Brain Res. 2019 Jul 6:112056.
Doi: 10.1016/j.bbr.2019.112056.
Epub ahead of print.

Infrared Thermography as an Indicator of Heat Loss in Fur-Chewing Chinchillas *(Chinchilla Lanigera)*

Łapiński S.[1], Orel J.[2], Niedbała P.[1], Kucharska W.[2], Jakubowska M.[2], Lisowska-Lis A.[3], Tombarkiewicz B.[2], Lis M.W.[2]

[1]Department of Swine and Small Animal Breeding, University of Agriculture in Kraków, Kraków, Poland.
[2]Department of Veterinary, Reproduction and Animal Welfare, Faculty of Animal Science, University of Agriculture in Kraków, Kraków, Poland.
[3]State Higher Vocational School in Tarnów, Polytechnic Institute, Tarnów, Poland.

Fur-chewing is a common problem in chinchilla (Chinchilla lanigera). It may affect the welfare of animals due to heat loss, thereby possibly impacting food and water intake to maintain body temperature. In this context, infrared thermography seems to be a suitable method of measuring heat emissions from the surface of objects. Sexually mature male domestic chinchillas were divided into two groups: "non-fur chewers", exhibiting normal behaviour (n = 25), and "fur chewers" displaying fur-chewing behaviour (n = 23). Food and water intake (mean ± SD) measured in the control animals amounted to 20.7 ± 4.52 g and 15.9 ± 3.45 mL, while in fur-chewing chinchillas were 25% and 33% higher, respectively. Metabolic energy intake, were calculated 2.2 and 2.8 W for the control and fur-chewing animals, respectively. Heat flux through chewed areas was 6.06 mW cm-2, which is 2.8 times higher than through undamaged chinchilla fur. To sum up, thermal imagingexplicitly shows that fur-chewing causes increased heat loss. Disturbances in the maintenance of thermal homeostasis may be an additional factor that reduces the welfare of these animals.

J Appl Anim Welf Sci. 2019 May 16:1-10.
Doi: 10.1080/10888705.2019.1614924. Epub ahead of print.

NUTRITION, FEEDING AND MANAGEMENT

Ginsenoside Rb1 promotes the growth of mink hair follicle via PI3K/AKT/GSK-3β signaling pathway

Zhang H.[1], Su Y.[2], Wang J.[3], Gao Y.[4], Yang F.[5], Li G.[6], Shi Q.[7]

[1]College of Animal Science and Technology, Hebei Normal University of Science and Technology, Qinhuangdao 066004, People's Republic of China; State Key Laboratory of Special Economic Animal Molecular Biology, Institute of Special Animal and Plant Sciences, Chinese Academy of Agricultural Sciences, Changchun 130112, People's Republic of China.
[2]College of Animal Science and Technology, Hebei Normal University of Science and Technology, Qinhuangdao 066004, People's Republic of China.
[3]Tangshan Municipal Station of Animal Husbandry, Tangshan 063000, People's Republic of China.
[4]Tangshan Animal Health Supervision Institute, Tangshan 063004, People's Republic of China.
[5]State Key Laboratory of Special Economic Animal Molecular Biology, Institute of Special Animal and Plant Sciences, Chinese Academy of Agricultural Sciences, Changchun 130112, People's Republic of China.
[6]State Key Laboratory of Special Economic Animal Molecular Biology, Institute of Special Animal and Plant Sciences, Chinese Academy of Agricultural Sciences, Changchun 130112, People's Republic of China. Electronic address: li_guangyu123@sina.com.
[7]College of Animal Science and Technology, Hebei Normal University of Science and Technology, Qinhuangdao 066004, People's Republic of China.

Life Sci. 2019 Jul 15; 229:210-218.
Doi: 10.1016/j.lfs.2019.05.033. Epub 2019 May 16.

In vivo fractionation of mercury isotopes in tissues of a mammalian carnivore *(Neovison vison)*

Ma L.[1], Evans R.D.[2], Wang W.[3], Georg R.B.[4]

[1]Environment & Life Sciences Graduate Program, Trent University, 1600 West Bank Drive, Peterborough, ON K9L 0G2, Canada.
[2]School of the Environment, Trent University, 1600 West Bank Drive, Peterborough, ON K9L 0G2, Canada.
[3]School of the Environment, Trent University, 1600 West Bank Drive, Peterborough, ON K9L 0G2, Canada.
[4]Water Quality Centre, Trent University, 1600 West Bank Drive, Peterborough, ON K9L 0G2, Canada.

Sci Total Environ. 2018 Jun 15; 627:1228-1233. Doi: 10.1016/j.scitotenv.2018.01.296. Epub 2018 Feb 7.

The challenges of recognising individuals with few distinguishing features: Identifying red foxes *Vulpes vulpes* from camera-trap photos

Dorning J.[1], Harris S.[1]

[1]School of Biological Sciences, University of Bristol, Bristol, United Kingdom.

Over the last two decades, camera traps have revolutionised the ability of biologists to undertake faunal surveys and estimate population densities, although identifying individuals of species with subtle markings remains challenging. We conducted a two-year camera-trapping study as part of a long-term study of urban foxes: our objectives were to determine whether red foxes could be identified individually from camera-trap photos, and highlight camera-trapping protocols and techniques to facilitate photo identification of species with few or subtle natural markings. We collected circa 800,000 camera-trap photos over 4945 camera days in suburban gardens in the city of Bristol, UK: 152,134 (19%) included foxes, of which 13,888 (9%) contained more than one fox. These provided 174,063 timestamped capture records of individual foxes; 170,923 were of foxes ≥ 3 months old. Younger foxes were excluded because they have few distinguishing features. We identified the individual (192 different foxes: 110 males, 49 females, 33 of unknown sex) in 168,417 (99%) of these capture records; the remainder could not be identified due to poor image quality or because key identifying feature(s) were not visible. We show that carefully designed survey techniques facilitate individual identification of subtly-marked species. Accuracy is enhanced by camera-trapping techniques that yield large numbers of high resolution, colour images from multiple angles taken under varying environmental conditions. While identifying foxes manually was labour-intensive, currently available automated identification systems are unlikely to achieve the same levels of accuracy, especially since different features were used to identify each fox, the features were often inconspicuous, and their appearance varied with environmental conditions. We discuss how studies based on low numbers of photos, or which fail to identify the individual in a significant proportion of photos, risk losing important biological information, and may come to erroneous conclusions.

PLoS One. 2019 May 9; 14(5):e0216531. Doi: 10.1371/journal.pone.0216531. eCollection 2019.

HEALTH AND DISEASE

Multicentric Molecular and Pathologic Study On Canine Adenovirus Type 1 in Red Foxes (*Vulpes vulpes*) in Three European Countries

Verin R.[1], Forzan M.[2], Schulze C.[3], Rocchigiani G.[1,2], Balboni A.[4], Poli A.[2], Mazzei M.[2]

[1]Department of Veterinary Pathology, Institute of Veterinary Science, University of Liverpool, Chester High Road, CH64 7TE Neston, UK.
[2]Department of Veterinary Science, University of Pisa, Viale delle Piagge 2, 56124 Pisa, Italy.
[3]State Laboratory Berlin-Brandenburg, 15236 Frankfurt (Oder), Germany.
[4]Department of Veterinary Medical Sciences, Alma Mater Studiorum-University of Bologna, Via Tolara di Sopra, 50-40064 Ozzano dell'Emilia, Bologna, Italy.

Canine adenovirus type 1 (CAdV-1) is the agent of infectious canine hepatitis, a severe frequently fatal disease affecting primarily dogs (*Canis lupus familiaris*). The virus has been detected in many wild carnivore species. Our aim was to evaluate the prevalence and genetic and histopathologic features of CAdV-1 in wild red foxes (*Vulpes vulpes*). Kidney and liver samples were obtained from 86 subjects, coming from the UK (*n*=21), Italy (*n*=36), and Germany (*n*=29). We used PCR, targeting the viral E3 gene and flanked regions, to detect the presence of the virus; viral E3, fiber, and E4 genes were sequenced and their sequences were compared with published sequences. Kidneys and liver from foxes in Italy and Great Britain (*n*=57) were prepared for histologic and immunohistochemical examination for CAdV-1. Viral DNA was detected in 22% (19 of 86) kidney samples, with E3 and E4 genes showing reported and unreported single nucleotide changes. No pathologic changes or viral immunopositive signals were detected in the examined tissues. Our study suggests that red foxes could be considered potential shedders of CAdV-1, as they showed a relatively

high prevalence without related pathologic changes in the organs examined.

J Wildl Dis. 2019 Jun 5. Epub ahead of print.

A comparative phylogenomic analysis of avian avulavirus 1 isolated from non-avian hosts: conquering new frontiers of zoonotic potential among species

Ul-Rahman A.[1,2], Shabbir M.Z.[3]

[1]Department of Microbiology, University of Veterinary and Animal Sciences, Lahore, 54600, Pakistan.
[2]Quality Operations Laboratory, University of Veterinary and Animal Sciences, Lahore, 54600, Pakistan.
[3]Quality Operations Laboratory, University of Veterinary and Animal Sciences, Lahore, 54600, Pakistan.

A number of avian avulavirus 1 (AAvV 1) isolates have been reported from avian and non-avian hosts worldwide with varying clinical consequences. In this regard, robust surveillance coupled with advanced diagnostics, genomic analysis, and disease modelling has provided insight into the molecular epidemiology and evolution of this virus. The genomic and evolutionary characteristics of AAvV 1 isolates originating from avian hosts have been well studied, but those originating from non-avian hosts have not. Here, we report a comparative genomic and evolutionary analysis of so-far reported AAvV 1 isolates originating from hosts other than avian species (humans, mink and swine). Phylogenetic analysis showed that AAvV 1 isolates clustered in five distinct genotypes (I, II, VI, VII and XIII). Further analysis revealed clustering of isolates into clades distant enough to be considered distinct subgenotypes, along with a few substitutions in several significant motifs. Although further investigation is needed, the clustering of AAvV 1 strains isolated from non-avian hosts into novel subgenotypes and the presence of substitutions in important structural and biological motifs suggest that this virus can adapt to novel hosts and therefore could have zoonotic potential.

Arch Virol. 2019 Jul; 164 (7):1771-1780.
Doi: 10.1007/s00705-019-04276-z.
Epub 2019 May 10.

First evidence of tick-borne protozoan pathogens, Babesia sp. and Hepatozoon canis, in red foxes *(vulpes vulpes)* in Serbia

Juwaid S.[1], Sukara R.[2], Penezić A.[1], Mihaljica D.[2], Veinović G.[2], Kavallieratos N.G.[3], Ćirović D.[1], Tomanović S.[2]

[1]Faculty of Biology, University of Belgrade, Belgrade, Serbia.
[2]Department of Medical Entomology, Center of Excellence for Food and Vector-borne Zoonoses, Institute for Medical Research, University of Belgrade, Dr Subotića 4, P.O. Box 39, 11129 Belgrade, Serbia.
[3]Laboratory of Agricultural Zoology and Entomology, Faculty of Crop Science, Agricultural University of Athens, Athens, Greece.

Tick-borne haematozoans cause severe diseases in domestic animals, and some of them have zoonotic potential. The results of previous studies in Europe point to the important role of foxes in natural endemic cycles of several tick-borne pathogens, including protozoa. The aim of the present research was to acquire information on the prevalence and distribution of tick-borne protozoan parasites among foxes in Serbia. Legally hunted foxes from 14 localities throughout Serbia were analysed. Spleen samples were collected from 129 animals and tested for the presence of Babesia spp. and Hepatozoon spp. by PCR. In total, 79/129 (61.2%) of the tested foxes were positive for H. canis, while the presence of two Babesia species was confirmed: B. vulpes (37/129, 28.7%) and B. canis (1/129, 0.8%). Coinfection with B. vulpes and H. canis was present in 26/129 (20.2%) foxes and one animal (1/129, 0.8%) was co-infected by B. canis and H. canis. The results of this study indicate the important role of foxes in the epizootiology of B. vulpes and H. canis in the Republic of Serbia and stress the need for further research to clarify all elements of the enzootic cycle of the detected pathogens, including other reservoirs, vectors, and transmission routes.

Acta Vet Hung. 2019 Mar; 67(1):70-80.
Doi: 10.1556/004.2019.008.

Baylisascaris procyonis infection in raccoons: A review of demographic and environmental factors influencing parasite carriage

French S.K.[1], Pearl D.L.[2], Peregrine A.S.[3], Jardine C.M.[4]

[1]Department of Pathobiology, Ontario Veterinary College, University of Guelph, 50 Stone Rd E, Guelph, ON N1G 2W1, Canada; Canadian Wildlife Health Cooperative, Ontario Veterinary College, University of Guelph, 50 Stone Rd E, Guelph, ON N1G 2W1, Canada.
[2]Department of Population Medicine, Ontario Veterinary College, University of Guelph, 50 Stone Rd E, Guelph, ON N1G 2W1, Canada; Canadian Wildlife Health Cooperative, Ontario Veterinary College, University of Guelph, 50 Stone Rd E, Guelph, ON N1G 2W1, Canada.
[3]Department of Pathobiology, Ontario Veterinary College, University of Guelph, 50 Stone Rd E, Guelph, ON N1G 2W1, Canada.
[4]Department of Pathobiology, Ontario Veterinary College, University of Guelph, 50 Stone Rd E, Guelph, ON N1G 2W1, Canada; Canadian Wildlife Health Cooperative, Ontario Veterinary College, University of Guelph, 50 Stone Rd E, Guelph, ON N1G 2W1, Canada.

Vet Parasitol Reg Stud Reports. 2019 apr; 16:100275.
Doi: 10.1016/j.vprsr.2019.100275.
Epub 2019 Feb 21.

Cardiopulmonary parasitic nematodes of the red fox *(Vulpes vulpes)* in Serbia

Gavrilović P.[1], Dobrosavljević I.[2], Vasković N.[3], Todorović I.[4], Živulj A[5], Kureljušić B.[6], Pavlović I.[7]

[1]Department of Pathology and Parasitology, Novoseljanski put 33, 26000 Pančevo, Serbia.
[2]Department of Pathology, Veterinary Specialized Institute 'Požarevac', Požarevac, Serbia.
[3]Department of Epizootiology, Veterinary Specialized Institute 'Kraljevo', Kraljevo, Serbia.
[4]Department of Animal Health, Novoseljanski put 33, 26000 Pančevo, Serbia.
[5]Department of Epizootiology, Veterinary Specialized Institute 'Pančevo', Novoseljanski put 33, 26000 Pančevo, Serbia.
[6]Department of Pathology, Belgrade, Serbia.
[7]Department of Parasitology, Scientific Veterinary Institute of Serbia, Belgrade, Serbia.

Among the wild canids, the red fox (Vulpes vulpes) is recognised as an important reservoir species for a range of parasites, including cardiopulmonary nematodes of public health and veterinary importance. As cross-host transmission between the red fox and domestic carnivores can play an important role in the epizootiology of cardiopulmonary parasitic diseases, the aim of the present investigations was to obtain data on the geographical distribution of cardiopulmonary nematodes of the red fox. The material for examination consisted of 83 foxes which were legally hunted at different locations during a three-month period from December 2017 to February 2018. The presence of four emerging species in Europe (Angiostrongylus vasorum, Crenosoma vulpis, Dirofilaria immitis and Eucoleus aerophilus) was revealed in red foxes of Serbia. Crenosoma vulpis and E. aerophilus were detected in foxes in both the plain and the mountainous areas across the country. Dirofilaria immitis is distributed in red foxes near alluvial rivers in Vojvodina province (northern Serbia). Angiostrongylosis caused by A. vasorum was demonstrated to exist in two enzootic foci with a high percentage of infected foxes in a plain area of northern Serbia. To the best of our knowledge, C. vulpis and A. vasorum were discovered for the first time in red foxes in central Serbia. The results provide strong evidence for veterinarians to take into consideration the parasitic nematodes discovered in red foxes in the differential diagnosis of diseases of companion animals. In the context of the 'One Health' approach the results related to the distribution of the zoonotic species E. aerophilus and D. immitis can be useful for medical epidemiology.

Acta Vet Hung. 2019 Mar; 67(1):60-69.
Doi: 10.1556/004.2019.007.

Genomic characterization of canine circovirus detected in red foxes *(vulpes vulpes)* from Italy using a new real-time pcr assay

De Arcangeli S.[1], Balboni A.[1], Kaehler E.[1], Urbani L.[1], Verin R.[2], Battilani M.[1]

[1]Department of Veterinary Medical Sciences, Alma Mater Studiorum-University of Bologna, Ozzano dell'Emilia, Bologna, Italy.

[2]*Department of Veterinary Pathology, Institute of Veterinary Sciences, University of Liverpool, Liverpool, UK.*

Data on canine circovirus circulation among red foxes (*Vulpes vulpes*) are limited. We report the detection of canine circovirus in a red fox from Italy. The virus was closely related to strains from dogs (*Canis lupus familiaris*) rather than those from foxes, suggesting a possible transmission between the two species.

J Wildl Dis. 2019 Jun 25. Epub ahead of print.

Crenosoma vulpis in red foxes (Vulpes vulpes) in Northern Italy

Morandi B.[1], Bertaso S.[2], Conboy G.[3], Gustinelli A.[2], Galuppi R.[2], Tosi G.[4], Poglayen G.[2]

[1]*Department of Veterinary Medical Sciences, Alma Mater Studiorum University of Bologna, via Tolara di Sopra 50, 40064, Ozzano Emilia, BO, Italy.*
[2]*Department of Veterinary Medical Sciences, Alma Mater Studiorum University of Bologna, via Tolara di Sopra 50, 40064, Ozzano Emilia, BO, Italy.*
[3]*Department of Pathology and Microbiology, Atlantic Veterinary College, Charlottetown, Prince Edward Island, C1A 4P3, Canada.*
[4]*Istituto Zooprofilattico Sperimentale della Lombardia e dell'Emilia Romagna "Bruno Ubertini"(IZSLER), sez. Forlì, Via don E. Servadei 3E/3F, 47122, Forlì, Italy.*

Crenosoma vulpis, the fox lungworm, is a nematode parasite of wild and domestic canids belonging to the super-family Metastrongyloidea. A survey of infection was carried out examining 88 red foxes (Vulpes vulpes) obtained during the regular hunting season (2014-2015) from the Emilia-Romagna region of Italy. Carcasses were stored frozen (- 21 °C) prior to necropsy. Lungs were examined for the presence of adult worms by dissection of the trachea, bronchi, and bronchioles, and then the lung tissue was examined for first-stage larvae (L1) by the Baermann method. No adult stages were detected, but L1, identified based on morphology as Crenosoma vulpis, were recovered from 28.4% (25/88) of the fox lungs. No significant differences in infection were found based on sex or geographical distribution. A brief review on C. vulpis report in red foxes in Italy and other European countries was also carried out.

Parasitol Res. 2019 Jun; 118(6):1981-1985.
Doi: 10.1007/s00436-019-06272-3.
Epub 2019 Apr 11.

Low concentration of serum immunoglobulin G is associated with pre-weaning diarrhea in young mink kits *(Neovison vison)*

Mathiesen R.[1], Chriél M.[2], Struve T.[3], Heegaard P.M.H.[4]

[1]*Innate Immunology Group, Section for Protein Science and Biotherapeutics, Department of Biotechnology and Biomedicine, Technical University of Denmark, Kemitorvet Building 204, 2800 Kgs., Lyngby, Denmark.*
[2]*Division of Diagnostics & Scientific Advice-Diagnostic & Development, National Veterinary Institute, Technical University of Denmark, Kemitorvet Building 204, 2800 Kgs., Lyngby, Denmark.*
[3]*Kopenhagen Fur, Langagervej 60, 2600, Glostrup, Denmark.*
[4]*Innate Immunology Group, Section for Protein Science and Biotherapeutics, Department of Biotechnology and Biomedicine, Technical University of Denmark, Kemitorvet Building 204, 2800 Kgs., Lyngby, Denmark.*

Background

Pre-weaning diarrhea (PWD) is a severe syndrome, with world-wide occurrence, affecting farmed mink (Neovison vison) kits during the lactation period. Kits affected by PWD often display clinical signs such as: yellow-white diarrhea, greasy skin, and dehydration. In severe cases the kits eventually die. It is common practice to treat PWD using antimicrobials; however the effect is not well documented. Due to the multifactorial etiology of PWD vaccine development is not feasible. The role played by the immune status of the mink kits with respect to their susceptibility to PWD is not well studied. To elucidate the possible association between PWD and total IgG serum concentration in young kits we analyzed blood collected from kits from 100 litters on two mink farms during the same breeding period, one farm being a case farm with high prevalence of PWD, and the other being a control farm with no cases of PWD.

Results

Kits affected by PWD had a significantly reduced weight gain compared to unaffected control kits. Litters born later in the breeding period came down with

PWD at an earlier age than litters born at the start of the breeding period. We found that PWD affected kits had significantly lower concentrations of serum IgG compared to unaffected kits at 13-15 days of age (the last blood sampling point of the study).

Conclusion

The results in this study suggest that PWD affected kits less efficiently absorbed IgG from maternal milk or had a lower intake of maternal milk, potentially contributing to the exacerbation of disease. A lower intake of IgG and/or less absorption from maternal milk could also pre-dispose kits for PWD. Future studies will be needed to elucidate if the circulating level of IgG is directly related to protection against disease and to investigate if administration of IgG could be helpful in alleviating and/or preventing PWD in mink kits.

Acta Vet Scand. 2019 Jun 10; 61(1):26.
Doi: 10.1186/s13028-019-0461-5.

Comparing the treatment effect of narrow spectrum antimicrobial, probiotic and fluid with amoxicillin in mink kits *(Neovison vison)* with pre-weaning diarrhea

Birch J.M.[1], Agger J.F.[2], Leijon M.[3], Ullman K.[3], Struve T.[4], Jensen H.E.[2]

[1]Department of Veterinary and Animal Sciences, Faculty of Health and Medical Sciences, University of Copenhagen, Frederiksberg, Denmark.
[2]Department of Veterinary and Animal Sciences, Faculty of Health and Medical Sciences, University of Copenhagen, Frederiksberg, Denmark.
[3]Department of Microbiology, National Veterinary Institute, Uppsala, Sweden.
[4]Kopenhagen Fur Diagnostics, Kopenhagen Fur, Glostrup, Denmark.

Res Vet Sci. 2019 Jun 3;125:121-129.
Doi: 10.1016/j.rvsc.2019.05.021. Epub ahead of print.

Infection of eight mesocarnivores in New Hampshire and Vermont with a distinct clade of canine distemper virus in 2016-2017

Needle D.B.[1], Burnell V.C.[1], Forzán M.J.[2], Dubovi E.J.[2], Schuler, K.L.[2], Bernier C.[5], Hollingshead N.A.[2], Ellis J.C.[3], Stevens B.A.[1], Tate P.[4], Anis E.[6, 7], Wilkes R.P.[7,8]

[1]New Hampshire Veterinary Diagnostic Laboratory, University of New Hampshire College of Life Sciences and Agriculture, Durham, NH.
[2]Department of Population Medicine and Diagnostic Sciences (Dubovi), and Animal Health Diagnostic Center, Wildlife Health Laboratory, Cornell University, College of Veterinary Medicine, Ithaca, NY.
[3]Northeast Wildlife Disease Cooperative, Cummings School of Veterinary Medicine at Tufts University, North Grafton, MA.
[4]New Hampshire Fish and Game Department, Concord, NH.
[5]Vermont Fish and Wildlife, Montpelier, VT.
[6]Department of Virology, Faculty of Veterinary Medicine, University of Sadat City, Sadat City, Beheira, Egypt.
[7]Department of Infectious Diseases, College of Veterinary Medicine, University of Georgia, Tifton GA.
[8]Department of Comparative Pathobiology/Animal Disease Diagnostic Laboratory, Purdue University College of Veterinary Medicine, West Lafayette IN.

Three fishers (*Martes pennanti*), 2 gray foxes (*Urocyon cinereoargenteus*), 1 mink (*Neovison vison*), 1 skunk (*Mephitis mephitis*), and 1 raccoon (*Procyon lotor*), from Vermont and New Hampshire, had lesions on autopsy consistent with canine distemper virus (CDV) infections diagnosed in a 12-mo period in 2016-2017. Lesions of CDV infection were most commonly noted in the lungs (8 of 8 animals), urothelium (5 of 8), biliary tract (5 of 8), gastrointestinal tract (4 of 7), and brain (4 of 6). Splenic lesions were seen in 3 animals. The diagnosis was confirmed via immunohistochemistry and virus isolation. Viral genotyping indicated that all 8 animals were infected with a distinct clade of CDV that has only been reported in wildlife in New England, and this clade of viruses is distinct from vaccine strains. During the 12 mo when these cases occurred, no other CDV clade was identified in any other wildlife or domesticated animal submitted from the 2 states.

J Vet Diagn Invest. 2019 Jul; 31(4): 562-567.
Doi: 10.1177/1040638719847510.
Epub 2019 Apr 25.

Safety and serological response to multivalent canine distemper virus vaccine in red foxes (vulpes vulpes)

Hidalgo-Hermoso E.[1,2], Mathieu-Benson C.[3,4], Celis-Diez S.[5], Soto-Guerrero P.[5], Carmona-Schmidt S.[6], Cabello-Stom J.[7], Ortiz-Tacchi C.[5,4]

[1]Departamento de Conservación e Investigación, Parque Zoológico Buin Zoo, Panamericana Sur Km 32, Buin, Chile, conservacion@buinzoo.cl.
[2]Departamento de Veterinaria, Parque Zoológico Buin Zoo, Panamericana Sur Km 32, Buin, Chile, conservacion@buinzoo.cl.
[3]Laboratorio de Virología, Laboratorio y Estación Cuarentenaria Pecuaria de Lo Aguirre, Servicio Agrícola y Ganadero, Kilómetro 12 de la ruta 68, Región Metropolitana, Chile.
[4]Escuela de Medicina Veterinaria, Universidad Mayor, Camino La Pirámide 5750, Santiago, Chile.
[5]Departamento de Veterinaria, Parque Zoológico Buin Zoo, Panamericana Sur Km 32, Buin, Chile.
[6]Departamento de Conservación e Investigación, Parque Zoológico Buin Zoo, Panamericana Sur Km 32, Buin, Chile.
[7]Facultad de Medicina Veterinaria, Universidad San Sebastián, sede de la Patagonia, Puerto Montt, Chile.

J Zoo Wildl Med. 2019 Jun 13; 50(2):337-341.
Doi: 10.1638/2018-0135.

Presence of Tapeworms (*Cestoda*) in Red Fox (*Vulpes Vulpes*) in North-western Poland, with Particular Emphasis on *Echinococcus Multilocularis*

Tylkowska A.[1], Pilarczyk B.[1], Pilarczyk R.[2], Zyśko M.[3], Tomza-Marciniak A.[1]

[1]Department of Animal Reproduction Biotechnology and Environmental Hygiene, Szczecin, Poland.
[2]Laboratory of Biostatistics, Faculty of Biotechnology and Animal Husbandry, West Pomeranian University of Technology in Szczecin, 71-270 Szczecin, Poland.
[3]Biebrza National Park, Osowiec-Twierdza 8, 19-110 Goniądz, Poland.

Introduction

Foxes are a reservoir of parasites that are dangerous to humans. The aim of the study was to determine the parameters associated with the occurrence of tapeworms in red foxes in north-western Poland.

Material and Methods

Parasitological sections were taken from 620 red foxes using IST and SCT methods in 18 districts of West Pomerania Province.

Results

The extensity of fox infection with tapeworms was 61%. *Echinococcus multilocularis*, *Mesocestoides* spp., *Dipylidium caninum*, and specimens of the genus *Taenia* were identified. *E. multilocularis* was found in 11 districts. *Mesocestoides* spp. demonstrated the highest prevalence (41.3%), while *E. multilocularis* demonstrated the lowest prevalence (2.9%); however, it infected foxes with the greatest mean intensity (235.6 tapeworms per fox). The most common co-occurrence in a single host organism was observed for *Mesocestoides* spp. and tapeworms of the genus *Taenia*; however, no examples were found of coinfection by *E. multilocularis* and *D. caninum*.

Conclusion

The occurrence of tapeworms in foxes was high in West Pomerania Province and was often higher than observed in previous years. For this reason, the risk of parasite transmission to humans and domestic animals is mounting. The risk of infection is also amplifying due to the growth of the fox population.

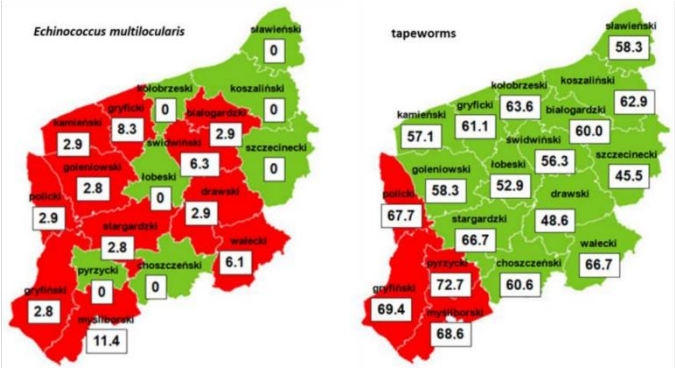

Fig. 1. Extensity of tapeworms and Echinococcus multilocularis infection (%) of red foxes in particular districts of West Pomerania Province; figures marked in red indicate the greatest extensity

J Vet Res. 2019 Mar 22; 63(1):71-78.
Doi: 10.2478/jvetres-2019-0005.
eCollection 2019 Mar.

Highly Pathogenic Swine Getah Virus in Blue Foxes, Eastern China, 2017

Shi N.[1], Li L.X.[2], Lu R.G.[3], Yan X.J.[3], Liu H.[1]

[1]*Foshan University, Foshan, China.*
[2]*Jilin Wildlife Rescue and Rehabilitation Center, Forestry Department of Jilin Province, Changchun, China.*
[3]*Chinese Academy of Agricultural Sciences, Changchun, China.*

We isolated Getah virus from infected foxes in Shandong Province, eastern China. We sequenced the complete Getah virus genome, and phylogenetic analysis revealed a close relationship with a highly pathogenic swine epidemic strain in China. Epidemiologic investigation showed that pigs might play a pivotal role in disease transmission to foxes.

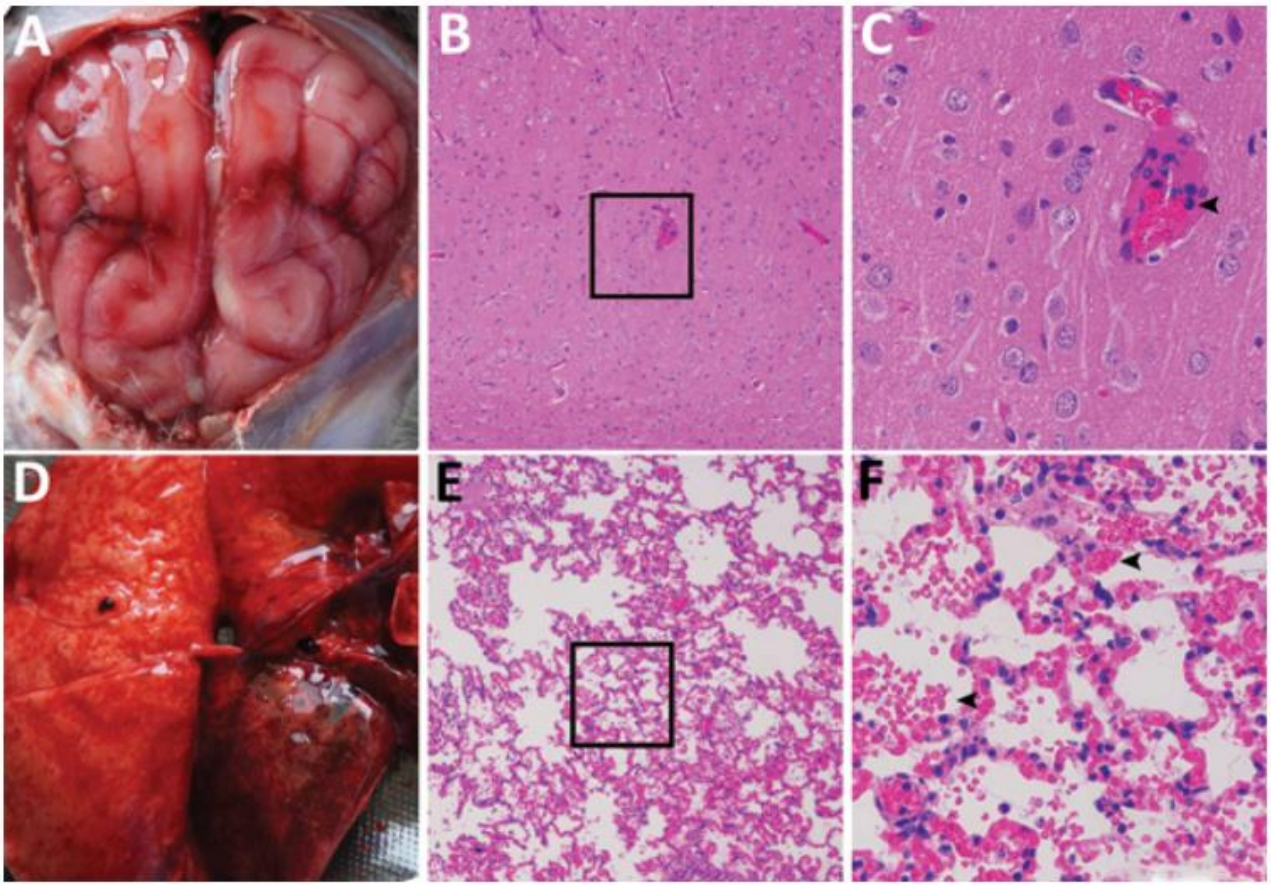

Fig. 1. Dissected brain and lung of a dead fox, collected in 2017 in Shandong Province, eastern China, and histopathologic examination of samples using hematoxylin and eosin staining. A) Brain, showing congestion in the meninx. B) Histologic view of meninx, showing mild neuronal degeneration and inflammatory cell infiltration in vessels. Original magnification ×100. Box indicates area enlarged in panel C. C) A higher magnification view (original magnification ×400) of lesions in panel B, showing inflammatory cell infiltration in a vessel (arrow). D) Lung tissue, showing extensive congestion and hemorrhage. E) Histologic view of lung tissue, showing congestion, hemorrhage, or both, with many erythrocytes in the alveolar space. Original magnification ×100. Box indicates area enlarged in panel F. F) A higher magnification view (original magnification ×400) of tissue lesions in panel E, showing erythrocytes in the alveolar space (arrows).

Emerg Infect Dis. 2019 Jun; 25(6):1252-1254.
Doi: 10.3201/eid2506.181983.

Southern California and range-wide raccoon gastrointestinal helminth database

Weinstein S.B.[1], Van Wert J.C.[2], Kinsella M.[3], Tkach V.V.[4], Lafferty K.D.[5]

[1]Department of Biology, University of Utah, Salt Lake City, UT, 84112, USA.
[2]Department of Ecology, Evolution, and Marine Biology, University of California, Santa Barbara, CA, 93106, USA.
[3]Helm West Laboratory, 2108 Hilda Avenue, Missoula, MT, 59801, USA.
[4]Department of Biology, University of North Dakota, Grand Forks, ND, 58202, USA.
[5]Western Ecological Research Center, U.S. Geological Survey c/o Marine Science Institute, University of California, Santa Barbara, CA, 93106, USA.

Ecology. 2019 Jul 1.
Doi: 10.1002/ecy.2807. Epub ahead of print.

Epidemiology and molecular characterization of the antimicrobial resistance of *Pseudomonas aeruginosa* in Chinese mink infected by hemorrhagic pneumonia

Bai X.[1], Liu S.[2], Zhao J.[1], Cheng Y.[1], Zhang H.[1], Hu B.[1], Zhang L.[1], Shi Q.[3], Zhang Z.[3], Wu T.[3], Luo G.[1], Lian S.[1], Xu S[1], Wang J.[1], Zhang W.[2], Yan X.[1]

[1]Key Laboratory of Special Animal Epidemic Disease, Ministry of Agriculture, Institute of Special Animal and Plant Sciences, Chinese Academy of Agricultural Sciences, Changchun, China.
[2]State Key Laboratory of Veterinary Biotechnology, Harbin Veterinary Research Institute, Chinese Academy of Agricultural Sciences, Harbin, China.
[3]Hebei Key Laboratory of Preventive Veterinary Medicine, Hebei Normal University of Science & Technology, Qinhuangdao, China.

Hemorrhagic pneumonia in mink is a fatal disease caused by *Pseudomonas aeruginosa*. Very little is known about *P. aeruginosa* in relation to genotype and the mechanisms underlying antimicrobial resistance in mink. A total of 110 *P. aeruginosa* samples were collected from mink from Chinese mink farms between 2007 and 2015. Samples underwent molecular genotyping using pulsed-field gel electrophoresis (PFGE) and multi-locus sequence typing (MLST), antimicrobial susceptibility and its mechanism were investigated at the molecular level. The PFGE identified 73 unique types and 15 clusters, while MLST identified 43 (7 new) sequence types (ST) and 12 sequence type clonal complexes (STCC). Sequence types and PFGE showed persistence of endemic clones in cities Wendeng (Shandong, China) and Dalian (Liaoning, China), even in different timelines. The MLST also revealed the gene correlation of the mink *P. aeruginosa* across different time and place. The ST1058 (n = 14), ST882 (n = 11), and ST2442 (n = 10) were the predominant types, among which ST1058 was the only one found both in Shandong province and Dalian (Liaoning, China). The MLST for *P. aeruginosa* infection in mink was highly associated with that in humans and other animals, implying possible transmission events. A small proportion of mink exhibited drug resistance to *P. aeruginosa* (9/69, 13%) with resistance predominantly to fluoroquinolone, aminoglycoside, and β-lactamase. Eight strains had mutations in the quinolone-resistance determining regions (QRDR). High proportions (65%; 72/110) of the *fosA* gene and 2 types of *glpt* deletion for fosmycin were detected. Furthermore, in the whole genome sequence of one multidrug resistant strain, we identified 27 genes that conferred resistance to 14 types of drugs.

Can J Vet Res. 2019 Apr; 83(2):122-132.

Aerosol Transmission of Gull-Origin Iceland Subtype H10N7 Influenza A Virus in Ferrets

Guan M.[1], Hall J.S.[2], Zhang X.[1], Dusek R.J.[2], Olivier A.K.[3], Liu L.[1], Li L.[1], Krauss S.[4], Danner A.[4], Li T.[5], Rutvisuttinunt W.[5], Lin X.[5], Hallgrimsson G.T.[6], Ragnarsdottir S.B.[7], Vignisson S.R.[8], TeSlaa J.[2], Nashold S.W.[2], Jarman R.[5], Wan X.F.[9]

[1]Department of Basic Science, College of Veterinary Medicine, Mississippi State University, Mississippi State, Mississippi, USA.
[2]United States Geological Survey National Wildlife Health Center, Madison, Wisconsin, USA.
[3]Department of Population and Pathobiology Medicine, College of Veterinary Medicine, Mississippi State University, Mississippi State, Mississippi, USA.
[4]Department of Infectious Diseases, St. Jude Children's Research Hospital, Memphis, Tennessee, USA.
[5]Viral Diseases Branch, Walter Reed Army Institute of Research, Silver Spring, Maryland, USA.

[6]*University of Iceland, Reykjavik, Iceland.*
[7]*Southwest Iceland Nature Research Centre, Sandgerdi, Iceland.*
[8]*Sudurnes Science and Learning Center, Sandgerdi, Iceland.*
[9]*Department of Basic Science, College of Veterinary Medicine, Mississippi State University, Mississippi State, Mississippi, USA wan@cvm.msstate.edu.*

J Virol. 2019 Jun 14;93(13). pii: e00282-19.
Doi: 10.1128/JVI.00282-19. Print 2019 Jul 1.

Ultrastructure and Nanomorphology of the American Mink *(Mustela vison)* Kidney

Ezhkov V.O.[1], Ezhkova M.S.[2], Yapparov I.A.[1], Yapparov A.K.[1], Nizameev I.R.[2], Nefed'ev E.S.[2], Ezhkova A.M.[3], Larina Y.V.[1]

[1]*Tatar Research Institute for Agricultural Chemistry and Soil Science, Kazan Scientific Center, Russian Academy of Science, 420059, Kazan, Tatarstan, Russia.*
[2]*Kazan National Research Technological University, 420015, Kazan, Tatarstan, Russia.*
[3]*Tatar Research Institute for Agricultural Chemistry and Soil Science, Kazan Scientific Center, Russian Academy of Science, 420059, Kazan, Tatarstan, Russia.*

The ultrastructure of the nephron subcellular organelles was studied in healthy mink kidneys. The data obtained were compared with the results of transmission electron microscopy. The renal cell nanomorphology proved to be similar when electronograms and the atomic force microscopy images were analyzed. The methods used enabled us to visualize the glomerular capillary endotheliocytes with cytolemma pits in the area of fenestrae that provide blood filtration; in the proximal nephron part, on the apical pole of the epithelial cells, brush-border soft microvilli were observed. The microvilli were characterized by a well-organized structure along their entire length and the membrane integrity. The data obtained show morphological parameters of the healthy mink organ and can be helpful in diagnosing of nephropathology.

Dokl Biol Sci. 2019 Mar; 485(1): 56-58.
Doi: 10.1134/S0012496619020091.
Epub 2019 Jun 13.

Comparison of intra- and inter-host genetic diversity in rabies virus during experimental cross-species transmission

Bonnaud E.M.[1], Troupin C.[1], Dacheux L.[1], Holmes E.C.[2], Monchatre-Leroy E.[3], Tanguy M.[1], Bouchier C.[4], Cliquet F.[3], Barrat J.[3], Bourhy H.[1]

[1]*Institut Pasteur, Unit Lyssavirus Dynamics and Host Adaptation, WHO Collaborating Centre for Reference and Research on Rabies, Paris, France.*
[2]*Marie Bashir Institute for Infectious Diseases and Biosecurity, Charles Perkins Centre, School of Life and Environmental Sciences and Sydney Medical School, The University of Sydney, Sydney, Australia.*
[3]*ANSES, Nancy Laboratory for Rabies and Wildlife, WHO Collaborating Centre for Research and Management in Zoonoses Control, OIE reference laboratory for rabies, European Union Reference Laboratory for rabies, European Union Reference Laboratory for rabies ser3ology, Malzéville, France.*
[4]*Institut Pasteur, Genomics Platform, Paris, France.*

The development of high-throughput genome sequencing enables accurate measurements of levels of sub-consensus intra-host virus genetic diversity and analysis of the role played by natural selection during cross-species transmission. We analysed the natural and experimental evolution of rabies virus (RABV), an important example of a virus that is able to make multiple host jumps. In particular, we (i) analyzed RABV evolution during experimental host switching with the goal of identifying possible genetic markers of host adaptation, (ii) compared the mutational changes observed during passage with those observed in natura, and (iii) determined whether the colonization of new hosts or tissues requires adaptive evolution in the virus. To address these aims, animal infection models (dog and fox) and primary cell culture models (embryo brain cells of dog and fox) were developed and viral variation was studied in detail through deep genome sequencing. Our analysis revealed a strong unidirectional host evolutionary effect, as dog-adapted rabies virus was able to replicate in fox and fox cells relatively easily, while dogs or neuronal dog cells were not easily susceptible to fox adapted-RABV. This suggests that dog RABV may be able to adapt to some hosts more easily than other host variants, or that when RABV switched from dogs to red foxes it lost its ability to adapt easily to other species. Although no difference in patterns of mutation variation between different host organs was observed, mutations were common following both in

vitro and in vivo passage. However, only a small number of these mutations also appeared in natura, suggesting that adaptation during successful cross-species virus transmission is a complex, multifactorial evolutionary process.

PLoS Pathog. 2019 Jun 20; 15(6):e1007799.
Doi: 10.1371/journal.ppat.1007799.
eCollection 2019 Jun.

Vaccine-associated rabies in red fox, Hungary

Forró B.[1], Marton S.[1], Kecskeméti S.[2], Hornyák Á.[3], Bányai K.[4]

[1]Institute for Veterinary Medical Research, Centre for Agricultural Research, Hungarian Academy of Sciences, Budapest, Hungary.
[2]Veterinary Diagnostic Directorate, National Food Chain Safety Office, Debrecen, Hungary.
[3]Veterinary Diagnostic Directorate, National Food Chain Safety Office, Budapest, Hungary.
[4]Institute for Veterinary Medical Research, Centre for Agricultural Research, Hungarian Academy of Sciences, Budapest, Hungary.

Vaccine. 2019 Jun 12; 37(27):3535-3538.
Doi: 10.1016/j.vaccine.2019.05.014.
Epub 2019 May 17.

Sarcoptic Mange of Fox Origin in Multiple Farm Animals and Scabies in Humans, Switzerland, 2018

Pisano S.R.R.[1], Ryser-Degiorgis M.P.[1], Rossi L.[2], Peano A.[2], Keckeis K.[3], Roosje P.[1]

[1]University of Bern, Bern, Switzerland.
[2]University of Turin, Grugliasco, Italy.
[3]Consulting veterinarian, Wabern, Switzerland.

Fox-derived Sarcoptes scabiei mites caused an outbreak of mange on a farm in Switzerland in 2018. Pruritic skin lesions suggestive of S. scabiei mite infestation developed in 4 humans who had direct contact with affected farm animals but not foxes. Sarcoptic mange is continuously spreading; such outbreaks affecting humans could start occurring more frequently.

Fig. 1 – below. Clinical and molecular characterization of an outbreak of fox-derived *Sarcoptes scabiei* mites in multiple mammal species on a farm in Switzerland, 2018. A) Outbreak timeline displaying animal species (pigs [*Sus scrofa domesticus*], oxen [*Bos taurus*], dogs [*Canis lupus familiaris*], goats [*Capra hircus*], horses [*Equus caballus*], and red foxes [*Vulpes vulpes*]) showing clinical signs compatible with sarcoptic mange and humans with signs of zoonotic scabies in order of appearance. Gray portion of arrow indicates the period during which clinical signs were observed in domestic animals and humans. Foxes with mange were observed in stables up to 3 weeks before the beginning of clinical signs in livestock. B–E) Clinical signs observed in a red fox (B; lethargy, severe hyperkeratosis), a pig (C; erythematous papules on shoulder and thorax), an ox (D; alopecia and erythema in the perineal region), and a teenage girl (E; erythematous papules on an arm). F) Multilocus microsatellite analysis demonstrating the genetic relationship of 10 individual mites isolated from a horse, an ox, a goat, and a fox at the farm where the outbreak occurred (black dots) and 48 additional mites from red foxes from the same region of Switzerland (population 1); Iberian ibex (*Capra pyrenaica*) from southern Spain (population 2); and wild boars (*Sus scrofa*) from Switzerland, nearby areas of France, and northern Italy (population 3). Neighbor-joining tree (left) constructed by using distance matrices with Populations version 1.2.28 (http://bioinformatics.org/populations) and displayed by using MEGA4 (http://www.megasoftware.net).
Tree branch lengths are proportional to the percent genetic distance. Bar plot (right) obtained with Structure 2.3.4 (https://web.stanford.edu/group/pritchardlab/structure.html) represents the cluster membership according to the analyses of 9 markers for K = 3 with the probability (0%–100%) for each mite to belong to a different population. Red indicates population 1, green indicates population 2, and blue indicates population 3. The 3 populations are the same as those in the distance tree. F, red fox; SI, Iberian ibex; WB, wild boar.

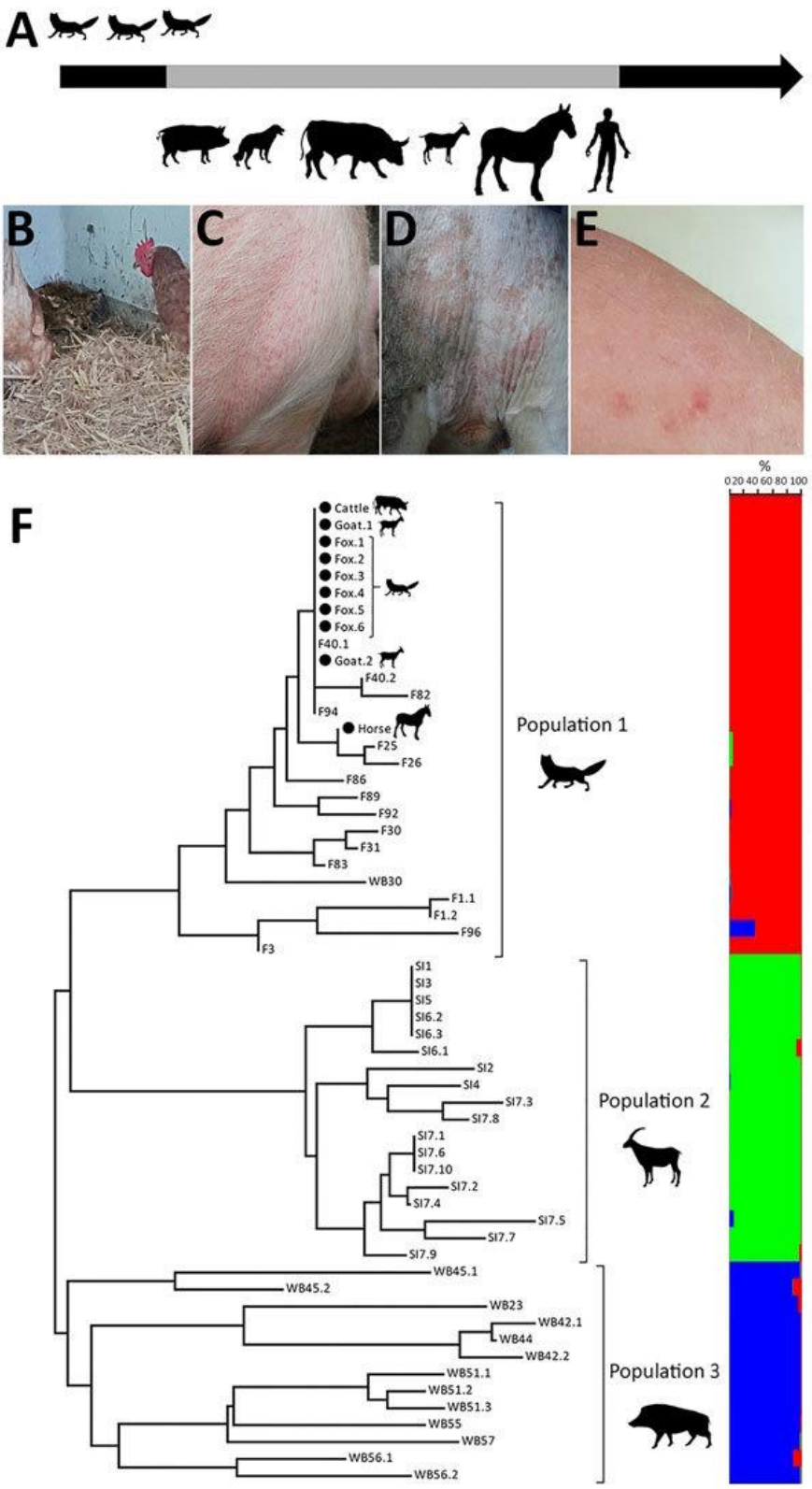

Emerg Infect Dis. 2019 Jun; 25(6): 1235-1238.
Doi: 10.3201/eid2506.181891.

Within-farm prevalence and environmental distribution of livestock-associated methicillin-resistant Staphylococcus aureus in farmed mink *(Neovison vison)*

Fertner M.[1], Pedersen K.[2], Jensen V.F.[1], Larsen G.[1], Lindegaard M.[1], Hansen J.E.[1], Chriél M.[3]

[1]National Veterinary Institute, Technical University of Denmark, Kemitorvet, DK-2800 Kgs Lyngby, Denmark.
[2]National Veterinary Institute, SE-751 89 Uppsala, Sweden.
[3]National Veterinary Institute, Technical University of Denmark, Kemitorvet, DK-2800 Kgs Lyngby, Denmark.

Vet Microbiol. 2019 Apr; 231:80-86.
Doi: 10.1016/j.vetmic.2019.02.032.
Epub 2019 Feb 23.

Experimental exposure of farmed mink *(Neovison vison)* to livestock-associated methicillin-resistant Staphylococcus aureus contaminated feed

Fertner M.[1], Pedersen K.[2], Chriél M.[3]

[1]National Veterinary Institute, Technical University of Denmark, Kemitorvet, DK-2800, Kgs Lyngby, Denmark.
[2]National Veterinary Institute, SE-751 89, Uppsala, Sweden.
[3]National Veterinary Institute, Technical University of Denmark, Kemitorvet, DK-2800, Kgs Lyngby, Denmark.

Vet Microbiol. 2019 Apr; 231:45-47.
Doi: 10.1016/j.vetmic.2019.02.033.
Epub 2019 Feb 23

Histopathological Lesions Caused by Experimental *Toxocara Canis* and *Toxascaris Leonina* Infections in Farm Mink (*Neovison Vison*)

Klockiewicz M.[1], Sobczak-Filipiak M.[2], Jakubowski T.[3], Długosz E.[1].

[1]Division of Parasitology and Invasioloy, Department of Pre-Clinical Sciences, Faculty of Veterinary Medicine, Warsaw University of Life Sciences, 02-786 Warsaw, Poland.
[2]Division of Pathology in Exotic, Laboratory, Non-domesticated Animals and Fish, Department of Pathology and Veterinary Diagnostics, Faculty of Veterinary Medicine, Warsaw University of Life Sciences, 02-786 Warsaw, Poland.
[3]Department of Large Animals Diseases with Clinic, Faculty of Veterinary Medicine, Warsaw University of Life Sciences, 02-797 Warsaw, Poland.

Introduction
Canine roundworm *T. canis* and *T. leonina* infections were investigated in experimentally infected farm mink (*Neovison vison*) to describe the pattern of pathological lesions in this paratenic host.

Material and methods
Material and MethodsInfections in mink developed following ingestion of embryonated eggs of either parasite or mice tissue infected with both parasite species.

Results
Comparative analysis of haematoxylin- and eosin-stained slides showed essential differences among the experimental groups. The lesions observed included eosinophil and mononuclear inflammatory infiltrates of the intestinal wall and local lymph nodes, inflammation and haemorrhages in liver tissues, and interstitial inflammation and mineralisation of the kidneys and lungs. Larvae migrating through the minks' bodies also caused particularly salient enlargement of lymphoid follicles in the spleen and inflammatory infiltrates of mononuclear cells in skeletal and heart muscles.

Conclusions
It is assumed that histopathological lesions appeared as a local and general host response to invasive L3 *T. canis* and *T. leonina* larvae migrating through the tissues of infected farm mink. Interestingly, mink infected with embryonated eggs had more pronounced lesions than animals infected with tissue larvae. Detailed histopathological examinations of parenchymal organs and striated muscles revealed lesions resembling those observed in other paratenic host species due to toxocarosis.

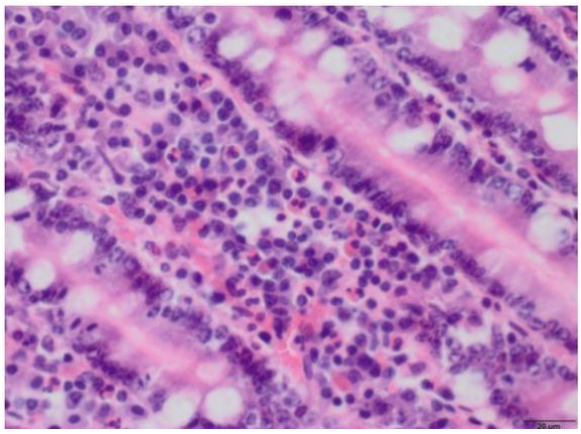

Fig. 1a. Inflammatory infiltrate with numerous eosinophils in the mucous membrane of small intestines – group 1 (mink infected with T. canis eggs)

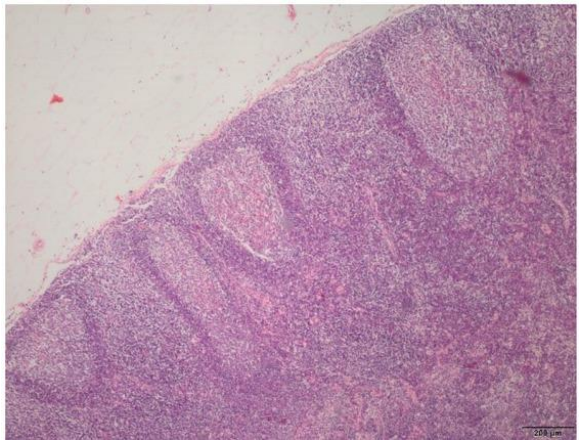

Fig. 1b. Secondary lymphatic nodules with germinal centres in the mesentery lymph node – group 4 (mink infected with *T. leonina* tissue larvae).

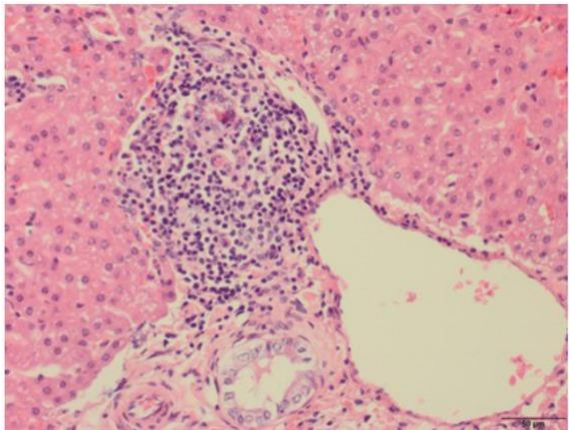

Fig. 2. Inflammatory infiltrate around the portal triad, fatty degeneration of hepatocytes – group 2 (mink infected with *Toxocara canis* larvae).

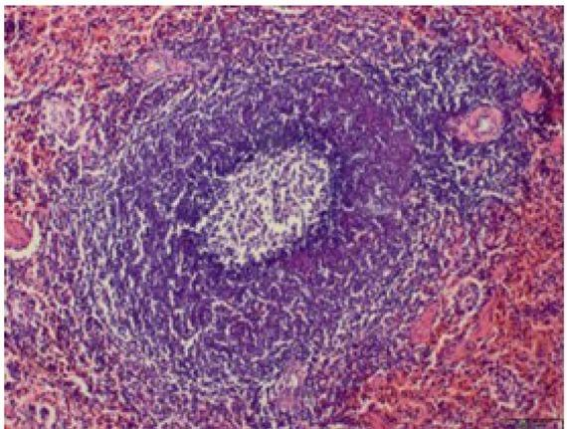

Fig. 3. Secondary follicle with germinal centre in the spleen, hyperaemia of the red matrix – group 4 (mink infected with *Toxascaris leonina* larvae).

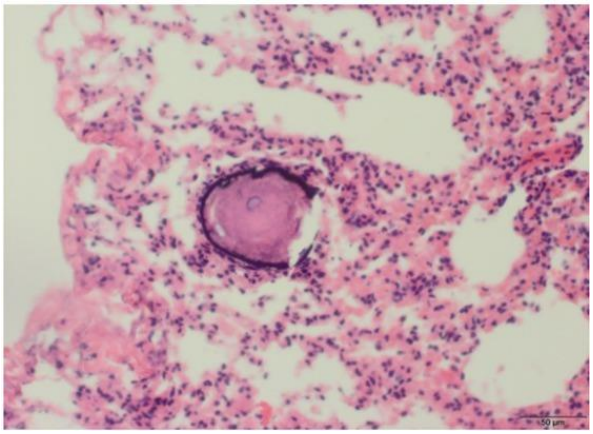

Fig. 4a. Mineralisation of *T. canis* larva and scant inflammatory infiltrate (predominantly macrophages and lymphocytes) in the lung parenchyma – group 1 (mink infected with *Toxocara canis* eggs).

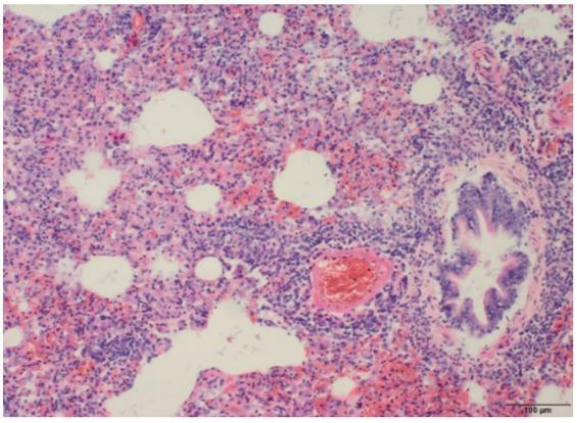

Fig 4b. Interstitial pneumonia – inflammatory infiltrates around vessels and bronchi – group 2 (mink infected with *Toxocara canis* tissue larvae).

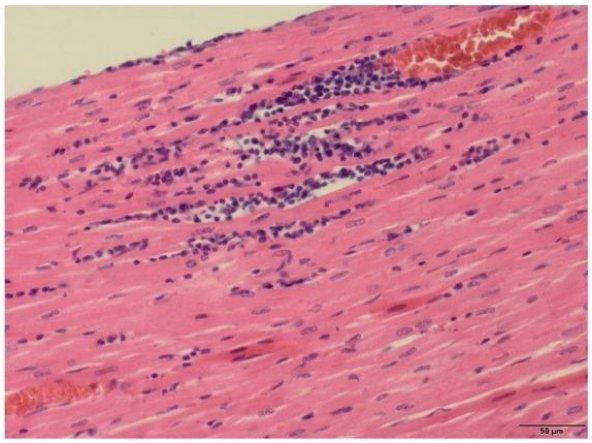

Fig. 5a. Inflammatory infiltrates of mononuclear cells around the vessel and among cardiomyocytes – group 3 (mink infected with *Toxascaris leonina* eggs)

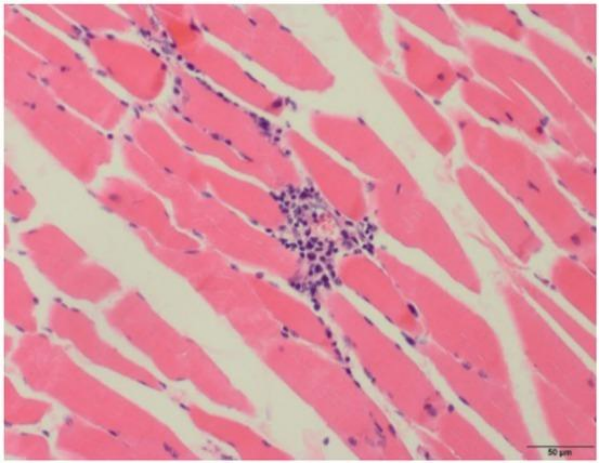

Fig. 5b. Inflammatory infiltrate of lymphocytes and macrophages around the vessel – skeletal muscle, group 1 (mink infected with *Toxocara canis* eggs).

J Vet Res. 2019 Jun 12; 63(2):205-214.
Doi: 10.2478/jvetres-2019-0034.
eCollection 2019 Jun.

Experimental Infection with *T. Canis* and *T. Leonina* in Farm Mink (*Neovison Vison*)

Klockiewicz M.[1], Jakubowski T.[2], Sobczak-Filipiak M.[3], Bartosik J.[1], Długosz E.[1]

[1]Division of Parasitology and Invasiology, Department of Pre-Clinical Sciences, Faculty of Veterinary Medicine, Warsaw University of Life Sciences, 02-786 Warsaw, Poland.

[2]Department of Large Animal Diseases with Clinic, Faculty of Veterinary Medicine, Warsaw University of Life Sciences, 02-797 Warsaw, Poland.
[3]Division of Pathology in Exotic, Laboratory, Non-domesticated Animals and Fish, Department of Pathology and Veterinary Diagnostics, Faculty of Veterinary Medicine, Warsaw University of Life Sciences, 02-786 Warsaw, Poland.

Introduction
Farm mink (*Neovison vison*) can be naturally exposed to *T. canis* and *T. leonina* pathogens on the farm. If mink were hosts, it would imply some veterinary public health as well as animal welfare issues. For this reason, the aim of the study was to determine whether mink might be definitive or paratenic hosts of these parasites.

Material and methods
Four groups of mink were infected with both parasite species using larvated eggs or feed containing mouse tissue previously infected with the parasites. Following inoculation, the infections were monitored *in vivo* by faecal examination for 14 weeks p.i., and then western blotting and ELISA were performed.

Results
Coprology did not reveal any canine roundworm eggs, neither were nematodes found in mink intestines during *post mortem* examination. The specific IgG antibodies recognising excretory/secretory (ES) antigens of both parasite species were identified in mink sera. Single *T. leonina* tissue larvae were found in digested organs.

Conclusions
Our results confirm that farm mink may contribute both *T. canis* and *T. leonina* infections. It was proved that farm mink were not their definitive hosts, and therefore mink faeces need not be considered a source of canine roundworm eggs in any soil it fertilises. Nonetheless, as farm mink may be a paratenic host for both parasite species, this may have some impact on the health and welfare of infected animals.

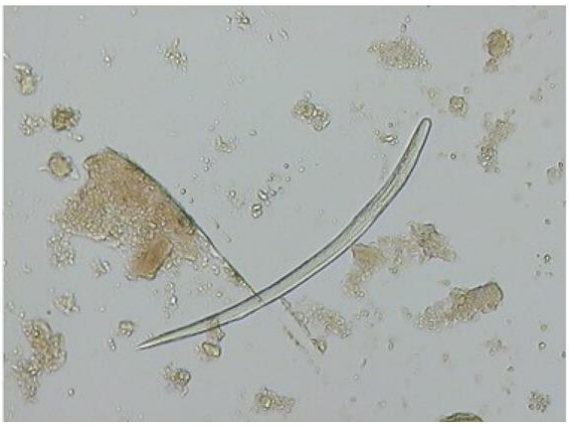

Fig. 1. *T. leonina* larva isolated from digested tissues of mink infected with eggs (G3).

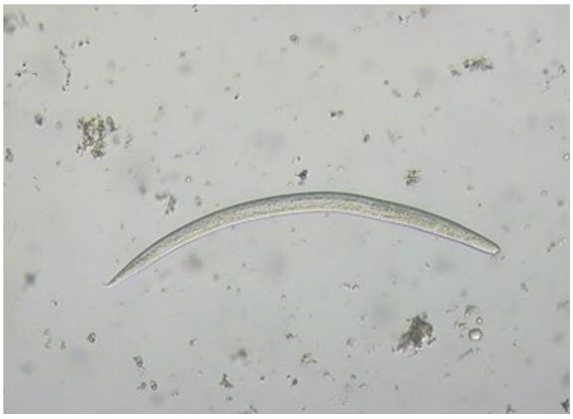

Fig. 2. *T. leonina* larva isolated from digested tissues of mink infected with tissue larvae (G4).

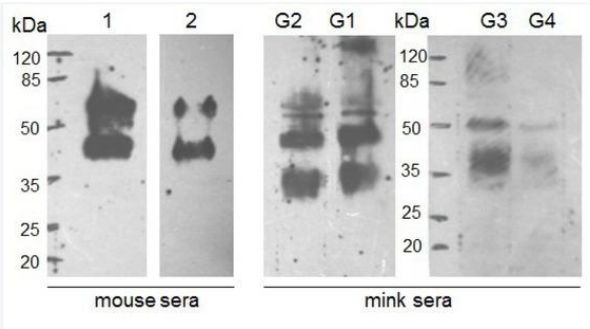

Fig. 3. Western blotting analysis of *T. canis*- and *T. leonina*-specific IgG antibodies in pooled sera from: 1 – mice infected with *T. canis*; 2 – mice infected with *T. leonina*; G1 – mink infected with *T. canis* eggs; G2 – mink infected with *T. canis* larvae in mouse tissue; G3 – mink infected with *T. leonina* eggs; G4 – mink infected with *T. leonina* larvae in mouse tissue.

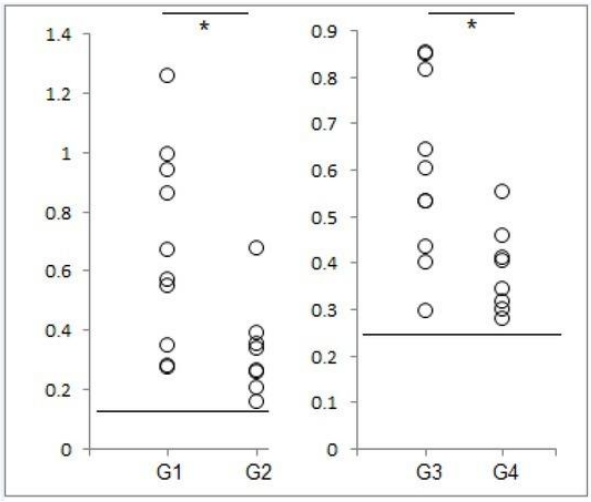

Fig. 4. IgG antibody response of mink to *T. canis* and *T. leonina* ES antigens determined by ELISA. Circles represent OD values from individual animals. Cut-off values were calculated as mean OD value from the control group +3×SD (marked as horizontal line). Statistically significant differences are marked with an asterisk ($P < 0.05$).

J Vet Res. 2019 Jun 12; 63(2):197-203.
Doi: 10.2478/jvetres-2019-0033.
eCollection 2019 Jun.

Dietary probiotics have different effects on the composition of fecal microbiota in farmed raccoon dog *(Nyctereutes procyonoides)* and silver fox *(Vulpes vulpes fulva)*

Peng Y.[1], Shi Q.[2], Wang Y.[3], Zhang F.[2], Ji Z.[2], Zhang J.[4]

[1]College of Biological, Chemical Sciences and Engineering, Jiaxing University, 118 Jiahang Road, Jiaxing, 314001, People's Republic of China..
[2]Hebei Normal University of Science and Technology, 360 Hebei Street, Qin Huangdao, 066004, People's Republic of China.
[3]College of Biological, Chemical Sciences and Engineering, Jiaxing University, 118 Jiahang Road, Jiaxing, 314001, People's Republic of China.
[4]College of Biological, Chemical Sciences and Engineering, Jiaxing University, 118 Jiahang Road, Jiaxing, 314001, People's Republic of China.

Background

The abuse of antibiotics in animal husbandry imposes a serious threat to both animal health and the environment. As a replacement for antibiotics, probiotic

products have been widely used in livestock farming to promote growth of animals. However, no products specifically developed for farmed raccoon dogs and foxes are commercially available at the moment. This study was conducted to investigate the effects of mixed probiotics on farmed raccoon dogs and foxes.

Results

Two feeding trials on farmed raccoon dogs and foxes were performed. A mixed probiotic preparation composed of Bifidobacterium bifidum, Clostridium butyricum, Bacillus subtilis and Bacillus licheniformis was fed to these two canine species in order to assess whether such a mixed probiotics can be an alternative to antibiotics (control group). The body weight of raccoon dogs exhibited an increasing tendency with mixed probiotics administration, while that of foxes did not. The serum antioxidant activity was evaluated, and a significantly increase of total antioxidative capacity (T-AOC) was observed in both species. Illumina MiSeq was used for the sequencing of 16S rRNA genes to compare the composition of fecal microbiota between the control and mixed probiotics groups. Although α-diversity did not change, β-diversity of the fecal microbiota showed a distinct dissimilarity between the control and probiotics groups of both raccoon dogs and foxes. Dietary mixed probiotics increased the abundance of the genus Bifidobacterium in the fecal samples of raccoon dogs, and the genus Bacillus in the fecal samples of foxes. The different responses of raccoon dogs and foxes to probiotics might be the result of differences in the composition of the native gut microbiota of the two species.

Conclusions

The mixed probiotics preparation composed of Bifidobacterium bifidum, Clostridium butyricum, Bacillus subtilis and Bacillus licheniformis could be an effective feed additive for the improvement of the health of farmed raccoon dogs, but it may not be suitable for foxes.

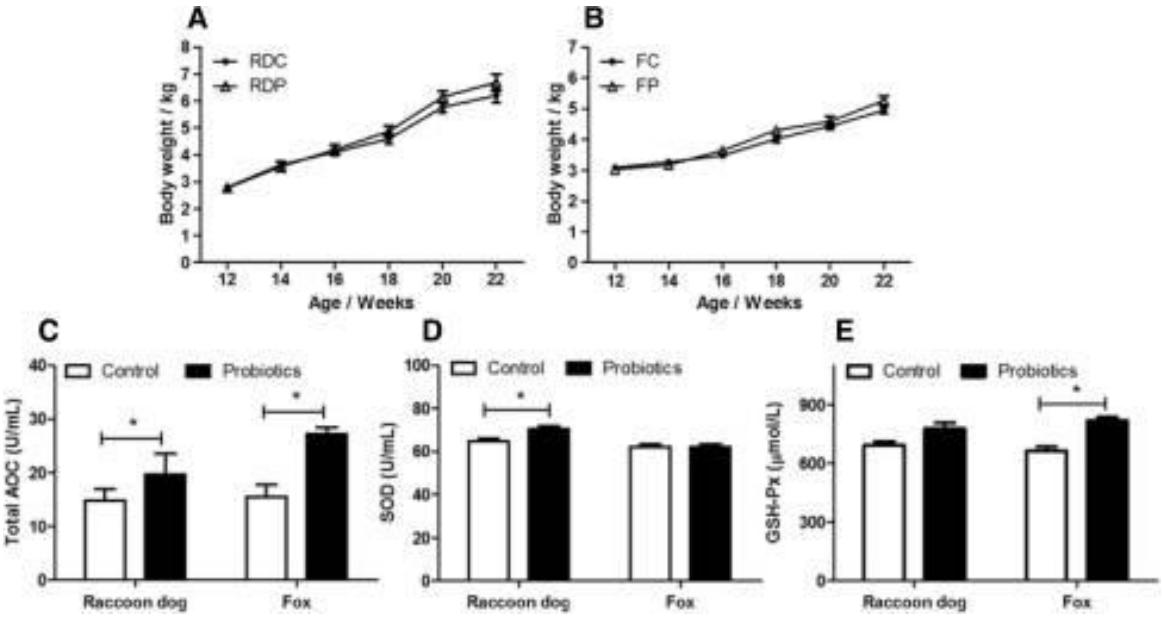

Fig. 1. The effect of dietary probiotics on the health performance of farmed raccoon dogs and foxes. (**a**): Body weight of raccoon dogs (*n* = 32 for each group). (**b**): Body weight of foxes (*n* = 32 for each group). (**c**): Total antioxidative capacity (T-AOC) (*n* = 8 for each group of raccoon dogs, *n* = 6 for each group of foxes). (**d**): Superoxide dismutase (SOD) activity (n = 8 for each group of raccoon dogs, *n* = 6 for each group of foxes). (**e**): Glutathione peroxidase (GSH-Px) activity (n = 8 for each group of raccoon dogs, *n* = 6 for each group of foxes)

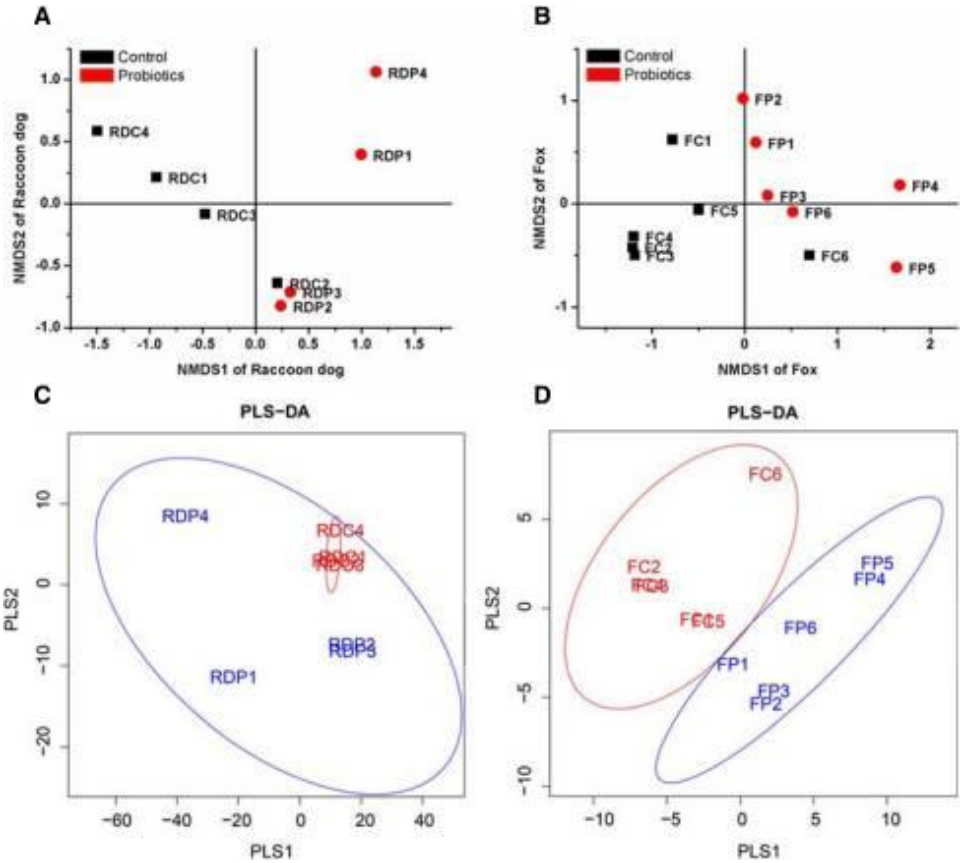

Fig. 2. Nonmetric multidimensional scaling (NMDS) ordination with weighted UniFrac distances of the control and probiotic treatment groups. Solid black squares represent control samples, and solid red circles represent probiotic-treated samples. (**a**): NMDS plot of raccoon dog control and probiotic groups. (**b**): NMDS plot of fox control and probiotic groups. Partial least squares discriminant analysis (PLS-DA) based on a supervised model was used to reveal the variation of microbiota between the control and probiotic groups; red circles represent control samples, blue circles represent probiotic samples. (**c**): PLS-DA plot of raccoon dog control and probiotic groups. (**d**) PLS-DA plot of fox control and probiotic groups.

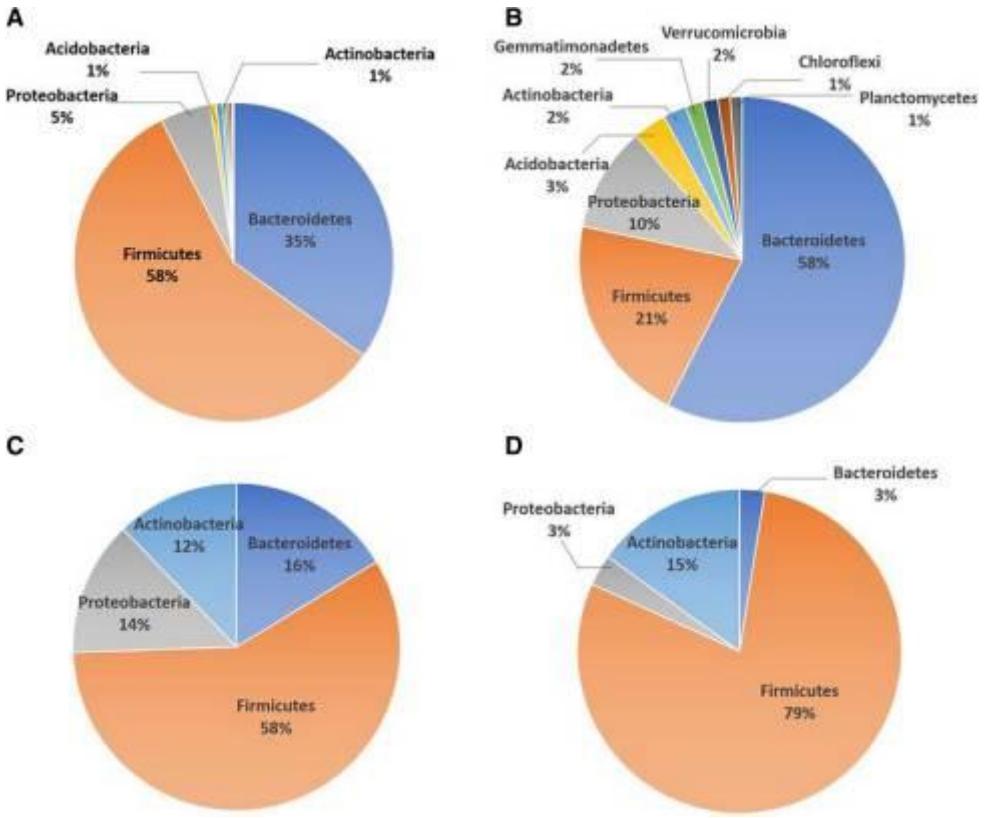

Fig. 3. Distribution of the fecal microbiota at the phylum level. (**a**): raccoon dog control group. (**b**): raccoon dog probiotic group. (**c**): fox control group. (**d**): fox probiotic group.

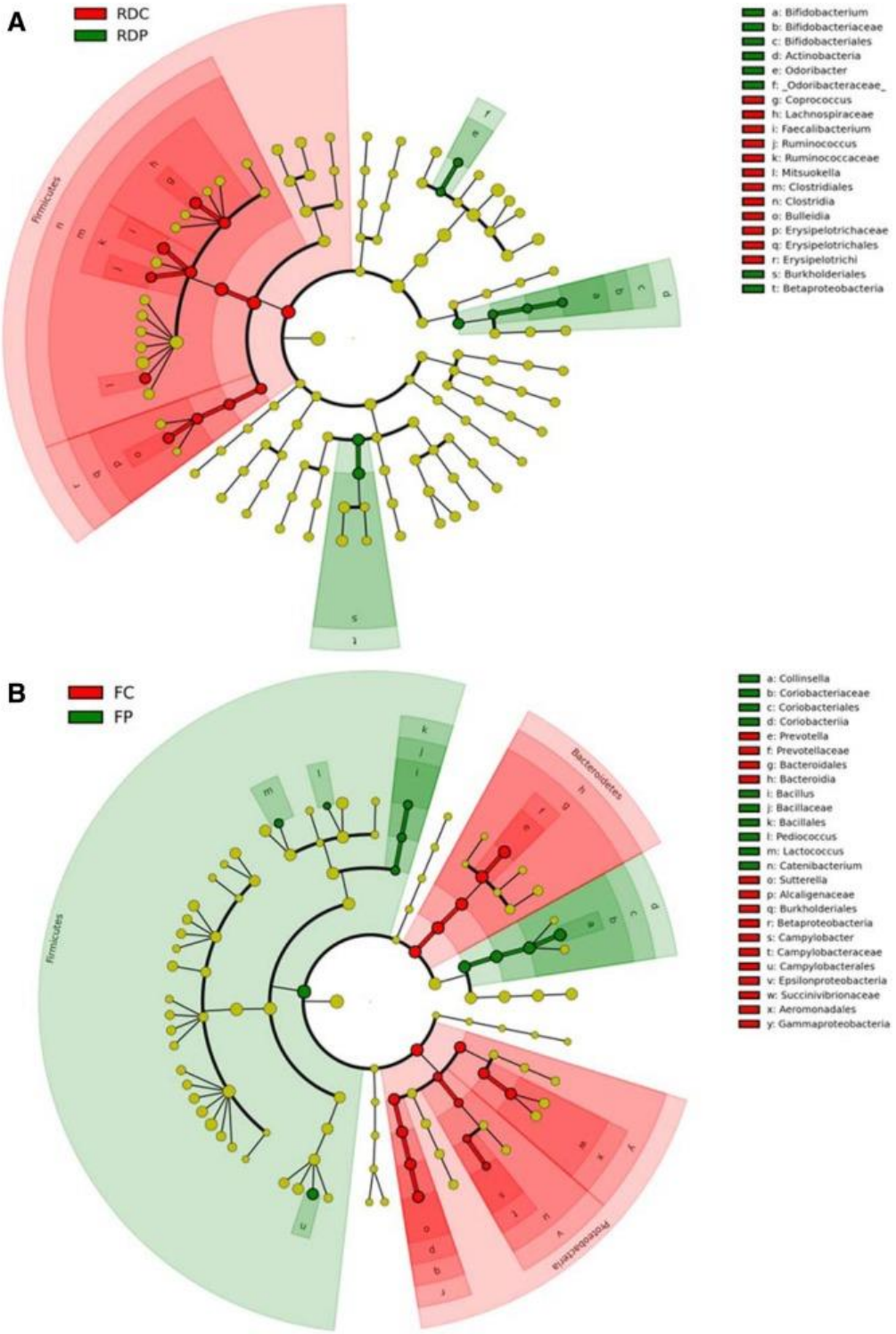

Fig. 4. Cladogram plotted from the data of the Linear discriminant analysis and effect size (LEfSe) analysis of the probiotic treatment and control groups. The green circles represent clades with significantly higher abundance in the probiotic treatment groups, red circles represent clades with significantly higher abundance in the control groups, and yellow circles represent microbial clades without significant differences of abundance between the groups. Concentric rings from inside to the outside denote the taxonomical levels of phylum, class, order, family and genus. (**a**): Differentially abundant microbial clades in the fecal samples of raccoon dogs from the group that underwent probiotic treatment (RDP, $n = 4$) versus control (RDC, n = 4). (**b**): Differentially abundant microbial clades in the fecal samples from foxes that underwent probiotic treatment (FP, $n = 6$) versus control (FC, $n = 6$).

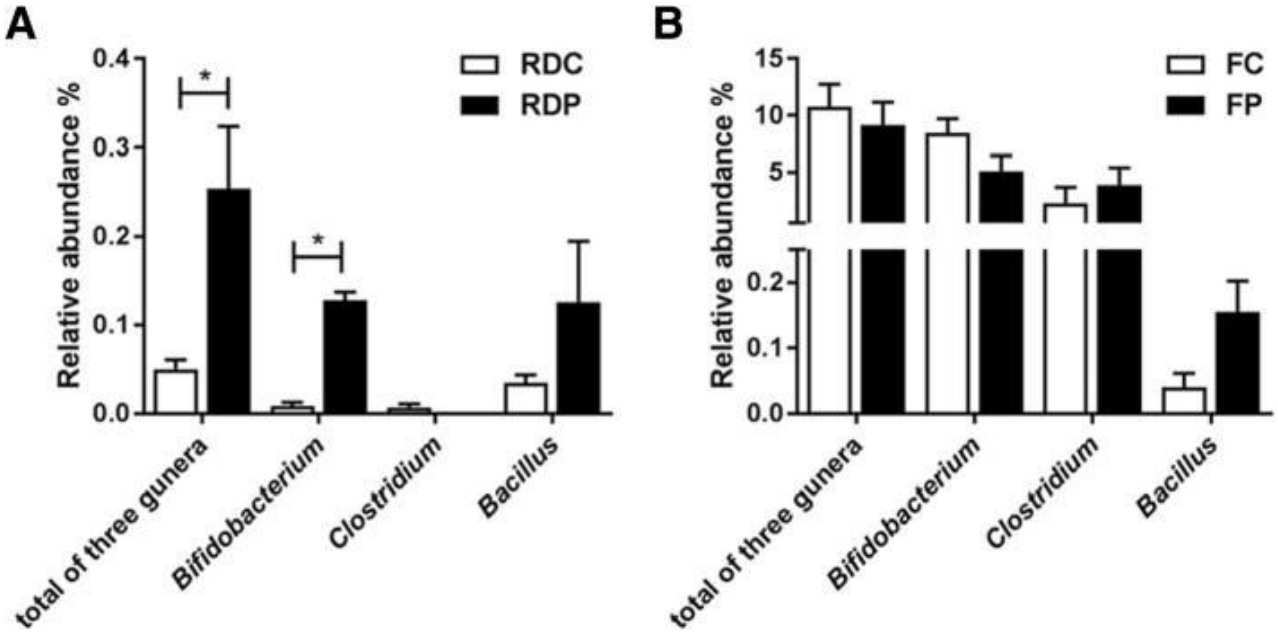

Fig. 5. Relative abundance of the genera added to the probiotic mixture. (**a**): Raccoon dog control and probiotic group. (**b**): Fox control and probiotic group.

BMC Microbiol. 2019 May 24; 19(1):109.
Doi: 10.1186/s12866-019-1491-x.

Prevalence of anticoagulant rodenticides in feces of wild red foxes *(Vulpes vulpes)* in Norway

Seljetun K.O.[1,2], Eliassen E.[3], Madslien K.[4], Viljugrein H.[4], Vindenes V.[3,5], Øiestad E.L.[3,6], Moe L.[1]

[1]Norwegian University of Life Sciences, Faculty of Veterinary Medicine, Department of Companion Animal Clinical Sciences, PO Box 369 Sentrum, 0102 Oslo, Norway.
[2]Norwegian Poisons Information Center, Norwegian Institute of Public Health, Division of Environmental Medicine, PO Box 222 Skøyen, 0213 Oslo, Norway.
[3]Oslo University Hospital, Division of Laboratory Medicine, Department of Forensic Sciences, PO Box 4450 Nydalen, 0424 Oslo, Norway.
[4]Norwegian Veterinary Institute, PO Box 750 Sentrum, 0106 Oslo, Norway.
[5]University of Oslo, Faculty of Medicine, Institute of Clinical Medicine, PO Box 1171 Blindern, 0318 Oslo, Norway.
[6]University of Oslo, School of Pharmacy, PO Box 1068 Blindern, 0316 Oslo, Norway.

High occurrence of anticoagulant rodenticides (ARs) in wildlife is a rising concern, with numerous reports of secondary exposure through predation. Because of widespread distribution of the red fox (*Vulpes vulpes*), they may act as sentinels for small mammal-hunting predators in rural, suburban, and urban areas. No AR surveillance in wild mammals with analyses of residues in feces has been conducted throughout a single country. We collected 163 fecal samples from presumed healthy red foxes from 18 out of 19 counties in Norway. The foxes were shot during regular hunting between January and December 2016 and samples collected directly after death. Fecal samples were analyzed for six ARs: brodifacoum, bromadiolone, coumatetralyl, difenacoum, difethialone, and flocoumafen. We detected ARs in 54% (75/139) of the animals. Brodifacoum was most frequently detected (46%; 64/139), followed by coumatetralyl (17%; 23/139), bromadiolone (16%; 22/139), difenacoum (5%; 7/139), difethialone (1%; 2/139), and flocoumafen (1%; 2/139). More than one substance was detected in 40% (30/75) of the positive foxes, and 7% (5/75) of these animals were exposed to four different ARs. There were no statistically significant seasonal, age, or sex differences in foxes after exposure to one AR compound. We found a significant difference in occurrence of brodifacoum and coumatetralyl in foxes from different geographical areas. These findings demonstrate fecal analyses as a valuable method of detecting AR exposure in red

foxes. We suggest using direct fecal sampling with analyses as a method to evaluate the occurrence of ARs in live endangered wildlife in connection with radio tagging or collaring operations.

J Wildl Dis. 2019 May 21. Epub ahead of print.

Rodent population cycle as a determinant of gastrointestinal nematode abundance in a low-arctic population of the red fox

Mørk T.[1], Ims R.A.[2], Killengreen S.T.[3]

[1]Norwegian Veterinary Institute, Section of Pathology, Stakkevollveien 23, NO-9010, Tromsø, Norway.
[2]Department of Arctic and Marine Biology, UiT - The Arctic University of Norway, NO-9037, Tromsø, Norway.
[3]Department of Education, UiT - The Arctic University of Norway, NO-9037, Tromsø, Norway.

We analyzed an 11-year time series (2005-2015) of parasite abundance for three intestinal nematode species in the red fox (*Vulpes vulpes*) as a function of the multi-annual rodent population cycle in low-arctic Norway, while correcting for other potential covariates that could influence prevalence and abundance. Rodents are paratenic and facultative intermediate hosts for the two Ascarididae species *Toxascaris leonina* and *Toxocara canis*, respectively and key prey for the red fox. Still the relative importance of indirect transmission through rodents and direct transmission through free-living stages is unclear. Abundance of these Ascarididae species in individual red foxes (N = 612) exhibited strongly cyclic dynamics that closely mirrored the 4-year rodent cycle. Negative binomial models provided evidence for a direct proportional increase in Ascarididae abundance with rodent density suggesting that predator functional response to rodent prey is the key transmission mechanism. In contrast, no cycles and constantly very low abundance were apparent for *Uncinaria stenocephala* - a third nematode species recorded without paratenic or intermediate stages.

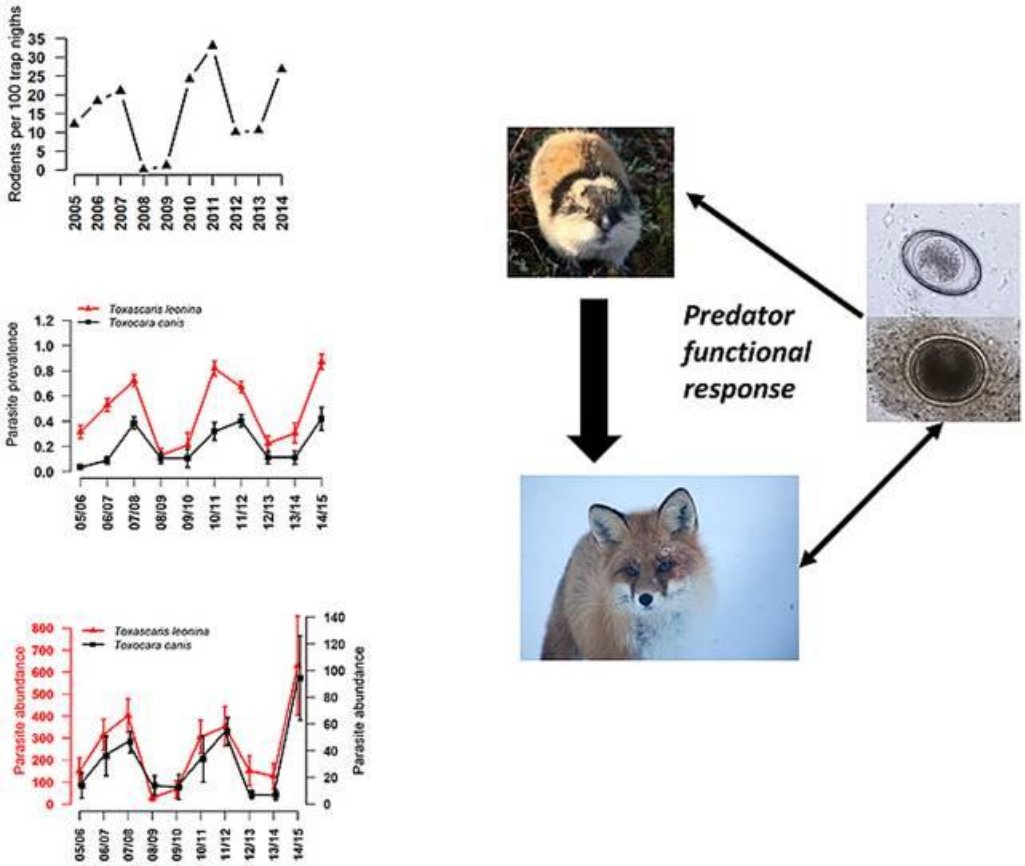

Graphical abstract.

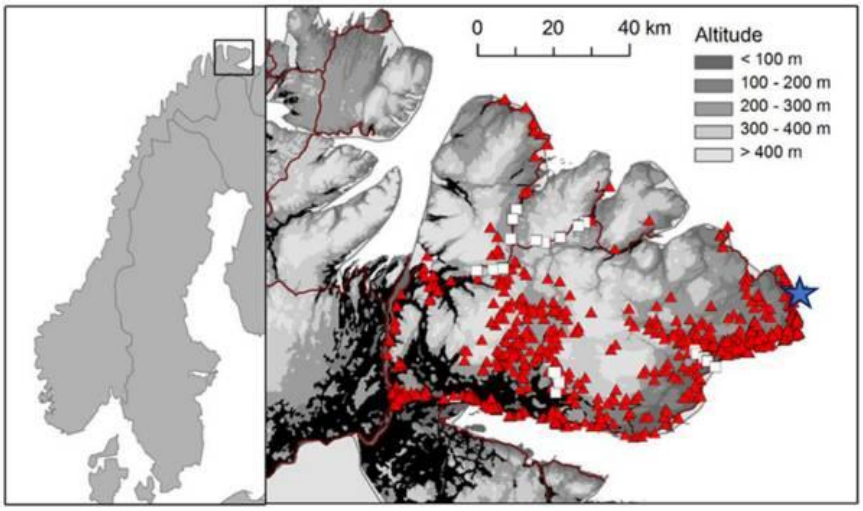

Fig. 1. Map showing the sampling sites on Varanger peninsula in northern Norway. Red triangles denote the sites where the 612 red foxes included in the analyses were. sampled. White squares denote sites where rodents were trapped for the purpose of monitoring their population dynamics. Dark areas are sub-arctic birch forest, while areas with different shading of grey show tundra at different altitudes. The meteorological station from which the climate data were derived, is denoted with a blue star. (For interpretation of the references to colour in this figure legend, the reader is referred to the Web version of this article).

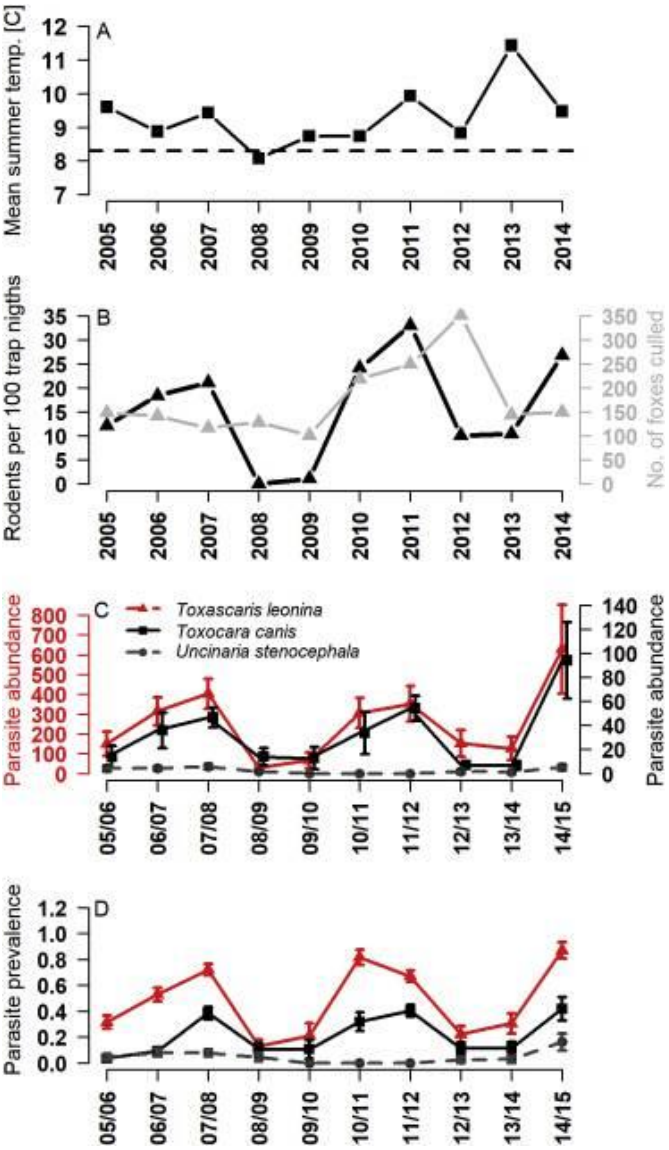

Fig. 2. Time series of annual climate variables, rodent density and egg counts of gastrointestinal parasites (i.e. number of eggs recorded) in red foxes faeces in Varanger Peninsula. A) The mean summer temperature (°C) for July, August and September from the weather station in Vardø (see Fig. 1). Horizontal broken lines show the 1960–1990 normal for temperature. B) Rodent density indexed as number of individuals caught per 100 trap nights in early September based on the trapping sites shown in Fig. 1 and number of foxes culled each winter season and local hunter (grey). Note that 2005 represents the foxes culled winter 2005–2006. C) Abundance (mean number of eggs per gram with standard error) of the three parasite species in the annual fox samples. Note the left (red) y-axis represents *T. leonina* while the right (black) y-axis represents *T. canis and U. stenocephala*. D) Prevalence (proportion of foxes with parasites, with standard error) of the three parasite species in the annual fox samples. (For interpretation of the references to colour in this figure legend, the reader is referred to the Web version of this article).

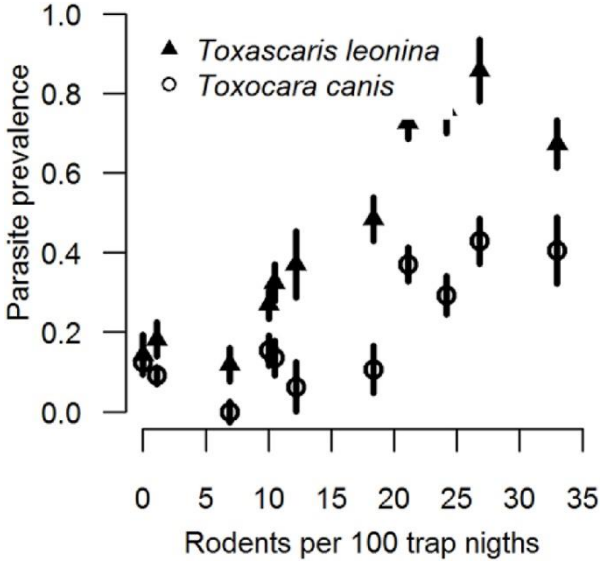

Fig. 3. Annual prevalence of the two Ascarididae species relative to rodent abundance the autumn preceding winter when the foxes were sampled.

Int J Parasitol Parasites Wildl. 2019 Mar 22; 9:36-41.
Doi: 10.1016/j.ijppaw.2019.03.002.
eCollection 2019 Aug.

SCIENTIFUR is published as four issues per year (one volume).

SCIENTIFIC ARTICLES. Papers submitted for publication as scientific articles are received with the understanding that the work has not been published before, and is not considered for publication elsewhere and has been read and approved by all authors. In regard to forwarded articles the author(s) alone is (are) responsible for the scientific content of the article. Experimental methods used and reported in SCIENTIFUR shall meet ethical standards of animal treatment.

MANUSCRIPTS
Manuscripts must be sent by e-mail, preferably in Microsoft Word. The material should be sent to: **E-mail: Scientifur@dca.au.dk.** In case of no access to e-mail, manuscripts can be forwarded to:
SCIENTIFUR, Danish Centre for Food and Agriculture, Aarhus University, P.O. Box 14, DK-8830 Tjele, Denmark

Manuscripts must be written in English, typed with double spacing and with page and line numbering and consisting of:

Title, which should be concise and informative, but as short as possible, and contain the main key words.

Authors name(s) as well as name(s) and address(es) of the institutions to which the work is attributed.
E-mail address of the corresponding author should be given.

Summary/Abstract.

Keywords in alphabetic order if not included in the title.

Text. The text should normally be divided into: Introduction, Material and Methods, Results, Discussion, Acknowledgements and References and follow internationally accepted rules. Double documentation in both figures and tables will not be accepted.

Illustrations. All graphs, photos and pictures are considered as figures. All drawings have to be professionally drafted (photocopies are not an acceptable standard). The illustrations should be JPG-, GIF- or TIF-files. Any halftones must exhibit high contrast and text and other details must be large enough to retain the readability even after reduction of figure size to single column (width 80 mm). The width of 170 mm can also be accepted. Colour illustrations can be included in SCIENTIFUR.

Tables. Each table should be typed on a separate page. Tables must be numbered consecutively with Arabic numerals, and have a self-explanatory title. Tables should be planned to fit a final width of 80 or 170 mm.

References. References in the text should be made according to the following examples:

Nielsen, 1992; Hansen & Berg, 1993; Bakken *et al*., 1999.

The list of references should be arranged in alphabetic order according to the name of the first author and the year of publication within the names. The year of publication should be written between the name(s) and the title:

Nielsen, V.H., Møller, S.H., Hansen, B.K. & Berg, P. (2007). Genotype - environment interaction in mink. *Scientifur*, 31 (3), 89.

Shirali, M., Nielsen, V.H., Møller S.H. & Jensen, J. (2015). Longitudinal analysis of residual feed intake and BW in mink using random regression with heterogeneous residual variance. *Animal*, 8 (10), 1597-1604.